

Disorders of Sex Development

Alejandro Diaz, MD,^{*,†} Elizabeth G. Lipman Diaz, PhD, ARNP, CPNP[‡]

^{*}Nicklaus Children's Hospital, Miami, FL

[†]Herbert Wertheim College of Medicine, Florida International University, Miami, FL

[‡]University of Miami School of Nursing and Health Studies, Coral Gables, FL

PRACTICE GAPS

Traditionally, ambiguous genitalia have been defined as a "medical and social emergency"; however, it is not. It requires a systematic, team-oriented approach.

Access to genetic testing and molecular diagnosis permits better understanding of conditions that produce ambiguous genitalia and allows better planning for gender assignment and further care.

OBJECTIVES *After completing this article, readers should be able to:*

1. Identify the most common causes of ambiguous genitalia in infants.
2. Understand basic imaging and laboratory tests for diagnosis.
3. Recognize the complexity of gender assignment and the need to partner with other medical specialties and the family for decision-making.
4. Recognize conditions that need immediate pharmacologic treatment to avoid medical complications.

INTRODUCTION

Disorders of sex development (DSDs), a vastly heterogeneous array of innate conditions, are secondary to abnormal development of sex chromosomes, as well as atypical growth of the gonads and genital anatomy. Specifically, DSDs result from insufficient virilization of the genitalia in a 46,XY fetus due to disorders of gonadal development, abnormal androgen synthesis, or disorders of androgen action, or secondary to the masculinization of the genitals of a 46,XX fetus. There is broad phenotypic expression of DSDs, ranging from minor variations of gonadal function and genital appearance to severely atypical gonads and genitalia.

The incidence of ambiguous genitalia at birth is estimated to be 1:4,500 to 1:5,500. (1) Among 46,XY individuals, the incidence of DSDs has been estimated to be 1:20,000 births; however, cryptorchidism and hypospadias are common congenital anomalies, occurring in 1:200 to 1:300 newborns. (1) Among 46,XX individuals,

AUTHOR DISCLOSURE Drs Diaz and Lipman Diaz have disclosed no financial relationships relevant to this article. This commentary does not contain a discussion of unapproved/investigative use of a commercial product/device.

ABBREVIATIONS

AMH	anti-müllerian hormone
CAH	congenital adrenal hyperplasia
CAIS	complete androgen insensitivity
CYP21A2	21-hydroxylase
CYP11B1	11 β -hydroxylase type 1
DHEA	dehydroepiandrosterone
5 α -DHT	5 α -dihydrotestosterone
DSD	disorder of sex development
EMS	external masculinization score
FSH	follicle-stimulating hormone
HCG	human chorionic gonadotropin
3 β -HSD2	3 β -hydroxysteroid dehydrogenase/isomerase type 2
17 β -HSD3	17 β -hydroxysteroid dehydrogenase type 3
LH	luteinizing hormone
NR5A1	nuclear receptor subfamily 5 group A, member 1
17-OHP	17-hydroxyprogesterone
PAIS	partial androgen insensitivity
5 α -RD2	5 α -reductase type 2
WT1	Wilms tumor suppressor gene

the most common cause of DSDs is congenital adrenal hyperplasia (CAH), which occurs in 1:14,000 to 1:15,000 live births. (1)

Prenatal karyotype evaluation as part of cell-free DNA testing is now common. Conditions such as complete androgen insensitivity (CAIS) or complete gonadal dysgenesis were often missed at birth or during infancy and childhood, and they can now be diagnosed sooner. This is due to affected newborns having a mismatch between their karyotype and the genital appearance on fetal ultrasonography or at birth.

In 2005, the Pediatric Endocrine Society and the European Society for Paediatric Endocrinology organized a meeting of international experts to create a consensus on the management of intersex disorders. At this meeting, new terminology was adopted, and terms such as *intersex*, *pseudohermaphroditism*, *hermaphroditism*, and *sex reversal*, as well as gender-based diagnostic labels, were replaced by *DSDs*, as defined by congenital conditions in which development of chromosomal, gonadal, or anatomic sex is atypical. (2) In this review, the consensus-recommended terminology is used.

EMBRYOLOGY

The development of normal genitalia (Fig 1) involves 2 processes: sex determination and sex differentiation. Sex determination depends on synchronized expression and interactions of genes and transcription factors that permit the formation and appropriate functioning of

the gonad. Sexual differentiation depends on the influence of gonadal and nongonadal hormones, which then transform embryonic structures into the genitals present at birth.

Testicular determination/formation depends on the presence of the *SRY* gene, on the Y chromosome, and encodes the testis-determining factor. The formation of the ovary requires the absence or dysfunction of *SRY* and a complex process that is beyond this review but is covered in the article by Tevosian and Manuylov. (3)

The urogenital ridges develop from the coelomic epithelium by week 4 to 6 of gestation. Thereafter, the gonads, adrenal cortex, kidneys, and reproductive tracts form from the urogenital ridges. Expression of *SRY* in pre-Sertoli cells at gestation week 7 triggers the activation of genes that produce testicular formation. Sertoli cells secrete anti-müllerian hormone (AMH), which produces regression of the müllerian ducts. Leydig cells produce testosterone, which is involved in the development and differentiation of the Wolffian duct structures (epididymis, vas deferens, and seminal vesicles). 5α -Dihydrotestosterone (5α -DHT), a metabolite of testosterone, is responsible for the development of the male external genitalia, urethra, and prostate. Both 5α -DHT and testosterone work through the same androgen receptor, but 5α -DHT has stronger affinity for this receptor.

Sexual differentiation in females depends on the absence of testosterone/ 5α -DHT and AMH. Müllerian ducts will form the fallopian tubes, uterus, cervix, and upper one-third of the vagina.

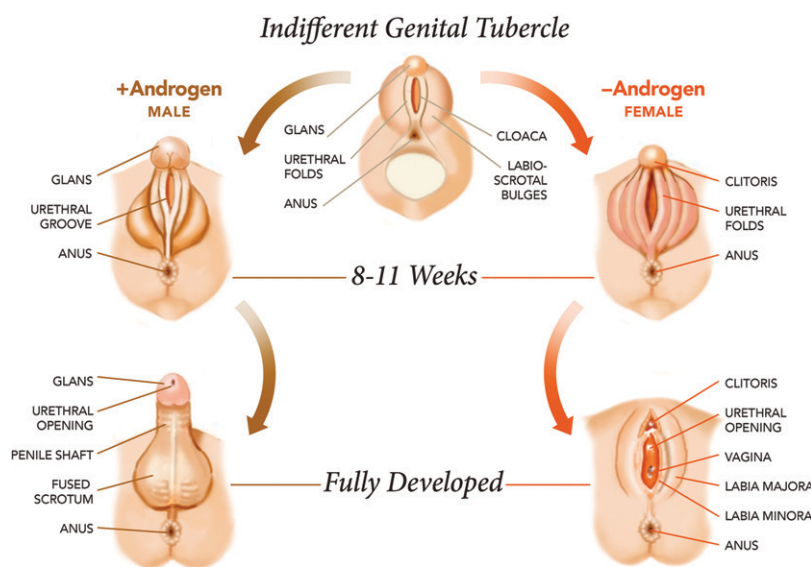


Figure 1. Fetal genital development.

Herein we present the most common conditions producing DSDs in four major groups: conditions produced by sex chromosome abnormalities, genetic mutations with 46,XY karyotype, genetic mutations with 46,XX karyotype, and conditions not caused by chromosomal or hormonal abnormalities.

SEX CHROMOSOMAL DSDS

Although Turner syndrome and Klinefelter syndrome are considered DSDs, individuals with these conditions do not have ambiguous genitalia.

Mixed gonadal dysgenesis is most often secondary to 45,X/46,XY karyotypes. Individuals with this condition have 2 gonadal germ cell lines, with testicular differentiation correlated with the proportion of 46,XY cells. (4) They have 1 streak gonad on one side and a dysgenetic fibrotic testicle with disordered tubular architecture on the other, retained müllerian structures, and incomplete genital masculinization. Due to the risk of developing gonadal neoplasia, early gonadectomy is recommended. (4)

Individuals with ovotesticular DSD have both testicular tissue with seminiferous tubules and ovarian tissue with follicles. They usually have ambiguous genitalia and gonads with testicular and ovarian tissue called ovotestes. Karyotypes of individuals with this condition are 60% 46,XX, 30% 46,XX/46,XY, and 10% 46,XY. (5)

Although not caused by abnormalities on sex chromosomes, gonadal dysgenesis is notable herein. It is characterized by a disruption of the gonadal development. Pure gonadal dysgenesis is defined as the absence of ovarian function (streak gonads) in a phenotypical female with a 46,XX or 46,XY karyotype. The term *complete gonadal dysgenesis* refers more specifically to 46,XY individuals with pure gonadal dysgenesis, female external genitalia, and müllerian derivatives. This condition is also known as Swyer syndrome.

46,XY DSDs

Disorders of Testicular Development

In 46,XY individuals, gonadal dysgenesis is secondary to defects in testicular development or differentiation. Abnormalities in more than 18 genes have been found to be related to 46,XY gonadal dysgenesis. The most common are loss-of-function mutations of *SRY*, *NR5A1(SF1)*, and *WT1*, and gain-of-function mutations of *MAP3K1* (Table 1). (6)(7)(8) If the gonads of these patients are not removed early in childhood, there is higher risk of developing gonadoblastomas and/or dysgerminomas. (9)

SRY Mutations. *SRY* is located on the end of the short arm of the Y chromosome and encodes the protein SRY, a transcription factor. When SRY activity is absent, the undifferentiated gonad does not become a testicle. Without testes, the 46,XY fetus will have female external genitalia and müllerian structures. Mutations in *SRY* are found in approximately 10% to 15% of patients with 46,XY gonadal dysgenesis. (9)

NR5A1 Mutations. The transcription factor NR5A1 (nuclear receptor subfamily 5 group A, member 1), previously known as steroidogenic factor 1, regulates genes related to the development of the gonads and adrenal glands. Mutations of the *NR5A1* gene explain approximately 20% of 46,XY gonadal dysgenesis and result in a wide spectrum of clinical manifestations: Swyer syndrome; 46,XY with female phenotype, clitoromegaly, palpable gonads with partial gonadal dysgenesis, and absence of müllerian derivatives; and 46,XY with oligospermia/azoospermia. Adrenal failure is rare in 46,XY patients with mutations on *NR5A1*. (10)

WT1 Mutations. 46,XY individuals with mutations of Wilms tumor suppressor gene (*WT1*) may, according to the location of the mutation, present with gonadal dysgenesis and renal disease as part of Frasier or Denys-Drash syndrome. Individuals with Frasier syndrome have female genitalia at birth, müllerian structures, as well as variable degrees of corticosteroid-resistant nephrotic syndrome due to

Table 1. Most Common Disorders of Testicular Development

VARIABLE	<i>SRY</i>	<i>NR5A1</i>	<i>WT1</i>	<i>MAP3K1</i>
Phenotype	Female	Variable, from female to male with oligospermia or azoospermia	Female: Frasier syndrome Ambiguous: Denys-Drash syndrome	Variable, from female to male with hypospadias and/or cryptorchidism
Müllerian structures	Present	Present or absent	Present in Frasier syndrome Absent in Denys-Drash syndrome	Present or absent
Other	Streak gonads	Adrenal failure is rare	Renal disease and high risk of Wilms tumor	Autosomal dominant or sporadic

segmental glomerulosclerosis. (4) Individuals with Denys-Drash syndrome have partial gonadal dysgenesis with undervirilized or ambiguous genitalia and absent müllerian structures. (4) They also have renal disease and will develop end-stage renal disease. Overlap of these conditions has been described. (11) Most individuals with *WT1* mutations have a high risk of developing Wilms tumors.

MAP3K1 Mutations. *MAP3K1* encodes a signal transduction factor essential for testicular development. Autosomal dominant or sporadic gain-of-function mutations of this gene have been identified in 46,XY individuals with complete gonadal dysgenesis and increased risk of gonadoblastoma and in individuals with partial gonadal dysgenesis who have incomplete testicular development, micropenis, hypospadias, and cryptorchidism. Recent data show that mutations on *MAP3K1* may account for 28% of patients with 46,XY DSDs with complete or partial gonadal dysgenesis. (7)(8)

Disorders in Androgen Biosynthesis

These autosomal recessive conditions (Table 2) are secondary to enzymatic defects that affect the production of testosterone or 5 α -DHT, with subsequent undermasculinization that correlates with the degree of enzymatic activity.

17 β -Hydroxysteroid Dehydrogenase Type 3 Deficiency. 17 β -hydroxysteroid dehydrogenase type 3 (17 β -HSD3) catalyzes the conversion of androstenedione to testosterone in

the testes. (12) The external genitalia of these patients are female in most cases. Some may have clitoromegaly or ambiguous genitalia with hypoplastic Wolffian duct derivatives and bilateral cryptorchidism characterized by inguinal masses. The biochemical diagnosis is made when the ratio of testosterone to androstenedione is less than 0.8 after a human chorionic gonadotropin (HCG) stimulation test. Most individuals with this condition are raised as females; during puberty, however, virilization often occurs due to extragonadal activity of other 17 β -hydroxysteroid dehydrogenases or residual gonadal 17 β -HSD3 activity. (12) In a report from Brazil, 5 of 15 individuals (33%) with this condition who were assigned as female at birth later changed their gender to male. None of those raised as male changed their gender. (13)

5 α -Reductase Type 2 Deficiency. 5 α -Reductase type 2 (5 α -RD2) catalyzes the conversion of testosterone to 5 α -DHT. 46,XY patients with this condition have different degrees of undermasculinization, from normal-appearing female external genitalia, to clitoromegaly without labial fusion, isolated micropenis, microphallus with differing degrees of hypospadias, and bilateral cryptorchidism. However, the most common presentation is female external genital with clitoromegaly, or microphallus with varying degrees of hypospadias. (14)

Historically, most patients with this condition were raised as girls. Typically, they presented with virilization at puberty due to increased activity of the 5 α -reductase type 1 enzyme and subsequent increase in testosterone levels. In

Table 2. Disorders in Androgen Biosynthesis

VARIABLE	17 β -HSD3 DEFICIENCY	5 α -RD2 DEFICIENCY	3 β -HSD2 DEFICIENCY	17 α -HYDROXYLASE /17,20-LYASE DEFICIENCY	LIPOID CAH
Phenotype	Most female, but ambiguous to hypospadias in milder forms	Variable: from female to male with hypospadias and/or cryptorchidism	From ambiguous genitalia to hypospadias	Female if complete deficiency; ambiguous genitalia if partial	Female
Characteristics	Masculinization during puberty; some develop gynecomastia; most are infertile	Masculinization during puberty; most are infertile	Three types: salt wasting, non-salt wasting, nonclassic	Hypokalemia and hypertension	No adrenal crisis the first months of life
Gender	If raised as female, 33% change gender role	If raised as female, 12%–50% change gender role	If raised as female, possible change gender role	Female if complete deficiency	Female
Treatment	Testosterone for penile enlargement in childhood and replacement at puberty	Testosterone and/or 5 α -DHT for penile enlargement and replacement at puberty	Glucocorticoid and mineralocorticoid replacement and sex hormone replacement at puberty	Glucocorticoid replacement and hormone replacement at puberty	Glucocorticoid and mineralocorticoid replacement and sex hormone replacement at puberty

CAH=congenital adrenal hyperplasia, 5 α -DHT=5 α -dihydrotestosterone, 3 β -HSD2=3 β -hydroxysteroid dehydrogenase/isomerase type 2, 17 β -HSD3=17 β -hydroxysteroid dehydrogenase type 3, 5 α -RD2=5 α -reductase type 2.

reports from Brazil and France, 16 of 30 individuals (53.3%) and five of 40 individuals (12.5%), respectively, who were assigned as female at birth changed their gender to male later in life. (13)(14) Patients assigned male at birth retained male gender identity independent of the degree of virilization at birth. (13) For this reason, male gender assignment is unlikely to result in gender change later in life.

3 β -Hydroxysteroid Dehydrogenase/Isomerase Type 2 Deficiency. This type of CAH is produced by mutations of 3 β -hydroxysteroid dehydrogenase/isomerase type 2 (3 β -HSD2), which is expressed in the adrenal glands and gonads and catalyzes the conversion of Δ^5 precursors into Δ^4 steroids, allowing the production of mineralocorticoids, glucocorticoids, and androgens. Its deficiency, therefore, produces deficiencies in all of these hormones but elevation of their precursors, such as dehydroepiandrosterone (DHEA). Male newborns are undervirilized due to lack of adequate androgen production in the testes. (15)

17 α -Hydroxylase/17,20-Lyase Deficiency. This type of CAH is produced by mutations of the *CYP17A1* gene. 46,XY individuals with this condition have a feminine phenotype due to low levels of testosterone, with hypertension and hypokalemia secondary to elevated mineralocorticoid levels. On laboratory evaluation they also have elevated gonadotropin, corticotropin, progesterone, and corticosterone levels, with low 17-hydroxyprogesterone (17-OHP) and renin levels. (15)

Lipoid CAH. Lipoid CAH is most often caused by mutations in steroidogenic acute regulatory protein, which moves cholesterol to the inner mitochondrial membranes to synthesize pregnenolone. This condition is more common among Japanese, Palestinian, and Korean individuals. Patients with lipoid CAH have impairment of adrenal and gonadal steroidogenesis. 46,XY individuals with this condition are born with female phenotype and absent müllerian derivatives; however, due to some steroidogenesis independent of steroidogenic acute regulatory protein, they do not develop adrenal crisis in the first months after birth. Elevation of the corticotropin level will produce hyperpigmentation and accumulation of cholesterol esters in steroid-producing cells, which will ultimately destroy these cells. (16)

Defects in Androgen Action

Androgen Insensitivity Syndrome. Defects in the androgen receptor prevent normal development of male genitalia and are the most common cause of male undermasculinization. The androgen receptor gene is located on the X-chromosome; therefore, androgen insensitivity syndrome has an X-linked pattern of inheritance, affecting only 46,XY individuals. According to the severity of the mutation, affected individuals

have CAIS or partial androgen insensitivity (PAIS). Persons with CAIS characteristically have female external genitalia and absent müllerian structures; therefore, they have a short vagina with a blind ending, absent Wolffian-derived structures, no prostate, and absent pubic and axillary hair as adults. They have normal breast development, normal to elevated testosterone levels, elevated estradiol and luteinizing hormone (LH) levels, and normal follicle-stimulating hormone (FSH) levels during and after puberty if the testicles are not removed before puberty. (17)(18) Feminization is secondary to aromatization of high levels of testosterone to estrogens. Individuals with PAIS have a wide spectrum of findings, according to the severity of the androgen receptor mutation. They may have female external genitalia with clitoromegaly and some degree of labial fusion, ambiguous genitalia with micropenis, perineal hypospadias, and cryptorchidism, or a well-formed penis with variable degrees of hypospadias, or isolated infertility. (18)

As previously mentioned, CAIS is often diagnosed when there is a mismatch between the prenatal karyotype and the genital appearance on fetal ultrasonography or at birth. Previously, this diagnosis was suspected when a prepubertal girl was found to have male gonads during evaluations of inguinal hernias or on evaluation for primary amenorrhea. Gonadectomy was frequently performed at the time of diagnosis due to suspected increased malignancy; however, recent data show that this risk is low. If gonads are not removed, the development of thelarche occurs at a normal age.

Leydig Cell Hypoplasia. Leydig cell hypoplasia is an autosomal recessive condition caused by loss-of-function mutations on the LH/HCG receptor, whose activation is essential for the maturation of Leydig cells and testosterone production. In 46,XY individuals, Leydig cell hypoplasia is characterized by various degrees of decreased virilization, from normal-appearing female genitalia with bilateral masses in the inguinal region to micropenis and/or hypospadias and/or cryptorchidism, low baseline testosterone levels without response to HCG stimulation, and elevated gonadotropin levels. (19)

46,XX DSDs

Disorders of Ovarian Development

Gonadal dysgenesis in a female is more commonly secondary to Turner syndrome with 45,X or 46,XX/45,X genotypes. Other causes of gonadal dysgenesis in 46,XX individuals are FSH receptor abnormalities and mitochondrial histidyl transfer RNA synthetase mutations.

Approximately 60% of individuals with ovotesticular DSD have a 46,XX karyotype. (5) They are caused by *SRY*

translocations, duplications of *SOX3* and *SOX9*, mutations in *RSPO1*, *WNT4*, *NR2F2*, or a specific mutation in *NR5A1*. Patients with *SRY* gene translocations to the X, or to an autosomal chromosome, explain most of these cases; they have ambiguous or male genitalia, small azoospermic testicles, and elevated gonadotropin levels. (20)

Androgen Excess

21-Hydroxylase Deficiency. 21-Hydroxylase (*CYP21A2*) deficiency is the most common cause of ambiguous genitalia in 46,XX individuals. Approximately 95% of the cases of CAH are caused by recessive mutations in *CYP21A2*, which converts 17-hydroxyprogesterone to 11-deoxycortisol and progesterone to deoxycorticosterone substrates for the synthesis of cortisol and aldosterone, respectively. The classic form affects approximately 1:14,000 to 1:15,000 newborns and is classified as either salt wasting, which happens in 75% of patients, or simple virilizing, which occurs in 25%. A milder, more common form, nonclassic CAH, affects 1:500 to 1:1,000 newborns. Females with the classic form have ambiguous genitalia, graded according to severity on the Prader scale from 1 to 5 (Table 3). (21) Some females with the nonclassic form have clitoromegaly. The diagnosis is facilitated in most developed countries by the implementation of newborn screenings.

11 β -Hydroxylase Type 1 Deficiency. 11 β -Hydroxylase type 1 (*CYP11B1*) deficiency represents 5% to 8% of CAH cases, affecting approximately 1:100,000 newborns. This condition is more common among the Moroccan Jewish population. *CYP11B1* converts 11-deoxycorticosterone and 11-deoxycortisol to corticosterone and cortisol, respectively. Due to the low production of cortisol, high corticotropin levels stimulate the production of androgens, and girls with this condition will have ambiguous genitalia. Two-thirds of patients with this condition will develop

hypertension in mid-childhood due to the high levels of 11-deoxycorticosterone, which has mineralocorticoid activity. This situation makes patients with *CYP11B1* deficiency less prone to developing adrenal crisis than patients with *CYP21A2* deficiency. (15)

3 β -HSD2 Deficiency. In this deficiency, elevation of the DHEA level, which is metabolized to some androgens, can produce mild virilization in the 46,XX individual. (15)

Fetoplacental Unit

Aromatase Deficiency. This is an autosomal recessive condition caused by mutations of *CYP19A1*, which encodes aromatase. This enzyme converts androgens into estrogens in gonadal and extragonadal tissues, including the placenta. Placental tissue from the fetus with aromatase deficiency is unable to convert DHEA sulfate from the fetal adrenal glands into estrogens, with the subsequent accumulation of its precursors, androstenedione and testosterone. Affected females are born with ambiguous genitalia, and their mothers develop virilization after the first trimester of pregnancy. Affected females may develop ovarian cysts during childhood, may not develop secondary sexual characteristics at the time of puberty, and may have primary amenorrhea and signs of hyperandrogenism. If untreated, males and females with this condition will develop osteoporosis, eunuchoid habitus, and tall stature. (22)

P450 Oxidoreductase Deficiency

Cytochrome P450 oxidoreductase is an electron donor for all microsomal P450 enzymes and other non-P450 enzymes. Mutations of this enzyme will affect the activity of enzymes involved in the synthesis of glucocorticoids, mineralocorticoids, and estrogens. According to the mutation, signs and symptoms vary from mild to

Table 3. Prader Scale

PRADER STAGE	PHALLUS	INTROITUS
0	Normal clitoris	Normal female
1	Mild clitoromegaly	Normal or slightly reduced vaginal opening
2	Moderate clitoromegaly	Mild posterior labial fusion; vagina and urethra have independent openings
3	Larger phallus, of penile appearance	Advanced posterior labial fusion of the labia minora; vagina and urethra share a common opening in the urogenital sinus at the base of the phallus
4	Phallus looks like a penis often with chordee	Complete labial fusion; the urogenital sinus becomes a penile urethra and opens at the shaft of the phallus
5	Phallus looks like a normal penis	Complete labial fusion; the urethra opens at or near the tip of the penis; normal-looking scrotum without gonads

severe. Ambiguous genitalia is usually seen in 46,XX and 46,XY newborns. Individuals with severe P450 oxidoreductase deficiency may also have skeletal anomalies such as craniosynostosis, flattened midface, prominent forehead, arachnodactyly, bowing of the thighs, and radiohumeral synostosis. This condition is known as Antley-Bixler syndrome. They also have choanal atresia, intellectual impairment, and developmental delay. Some of these newborns are born to mothers who became virilized during pregnancy due to deficiency of aromatase activity. (23)

Maternal Luteomas. Pregnancy luteomas are benign nonneoplastic lesions of the ovaries produced by increased activity of luteinized cells under stimulation by HCG producing androgens. Approximately two-thirds of newborn girls born to virilized mothers will have a certain degree of virilization. (24)

Krukenberg Tumors

Krukenberg tumors of the ovaries are produced by metastatic adenocarcinomas from gastrointestinal tissues or the breast. Due to luteinization of the tumoral stroma, these tumors may produce androgens. During pregnancy, androgen production is higher due to elevated HCG levels. This will produce virilization of the pregnant woman and the female fetus due to placental passage of elevated androgen levels. (24)

NONHORMONAL/NONCHROMOSOMAL DSDS

In cloacal exstrophy, aphallia, or some individuals with severe micropenis, the process of tubulization and cavitation of the caudal end of the embryo is affected, leaving an open bladder and exposing the abdominal organs. The phallic development in these individuals is highly abnormal; however, the gonads are usually unaffected. (25)

DIAGNOSIS (FIG 2)

Physical Examination

Evaluation of the child with a DSD should start with a complete physical examination, including anthropometric measurements, skin assessment, identification of any midline defects and/or dysmorphic features that may be part of syndromes that include ambiguous genitalia. Jaundice is commonly seen in patients with hypopituitarism, and hyperpigmentation is seen in patients with CAH. Patients with DSDs present with 1 of the following: apparent female genitalia and clitoromegaly with variable degrees of posterior labial fusion; apparent male genitalia with

micropenis, with or without palpable gonads; or variable degrees of hypospadias.

In general, the Prader scale (Table 3) has been used as a basic method to evaluate the degree of genital virilization in patients with CAH and other DSDs. (21) However, use of the external masculinization score (EMS) is a more precise method to evaluate the extent of masculinization of the external genitalia. The EMS is calculated based on the site of the urethral meatus (3 indicates normal; 2, distal hypospadias; 1, medial hypospadias; and 0, proximal hypospadias), locations of the gonads (for each gonad: 1.5 indicates labioscrotal; 1, inguinal; and 0, abdominal), size of the penis (3 indicates normal; 0, micropenis), and presence of labioscrotal fusion (3 indicates fusion; 0, absent). A normal male has a score of 12 and a normal female has a score of 0. (26)

Hypospadias is an abnormal location of the urethral meatus at the ventral side of the phallus, scrotum, or perineum, and it is classified as distal (glandular or subcoronal), medial (distal penile or midshaft), or proximal (penoscrotal or perineal). (27) When hypospadias is proximal, it produces a curvature of the phallus (chordee). Stretched penile length is measured by placing a ruler on the posterior aspect of the stretched penis and calculating the distance between the tip of the glans and the pubic symphysis. (27) A stretched penile length of less than -2 or -2.5 SD in any boy, or less than 2.5 cm in a term male newborn, is defined as micropenis. (28)

The anogenital ratio is a marker of androgen exposure during the first trimester of gestation. In girls, it is calculated as the measure from the anus to the posterior fourchette, divided by the distance between the anus and the base of the clitoris. Mean \pm SD anogenital ratio is 0.37 ± 0.07 in infants and 0.36 ± 0.07 in adults. An anogenital ratio greater than 0.5 suggests androgen-induced labioscrotal fusion and indicates a need for further evaluation. (29)

Laboratory Evaluation

Evaluation of sex chromosomes is one of the first tests to perform in an apparent male child with a low EMS, bilateral cryptorchidism, or severe hypospadias. Infants with an EMS greater than 11 do not warrant consideration for endocrine or genetic investigation. (30) Quantitative fluorescence polymerase chain reaction allows identification of sex chromosomes with results within 1 to 2 days. In addition, a karyotype, which takes longer to be completed and reported, should be ordered

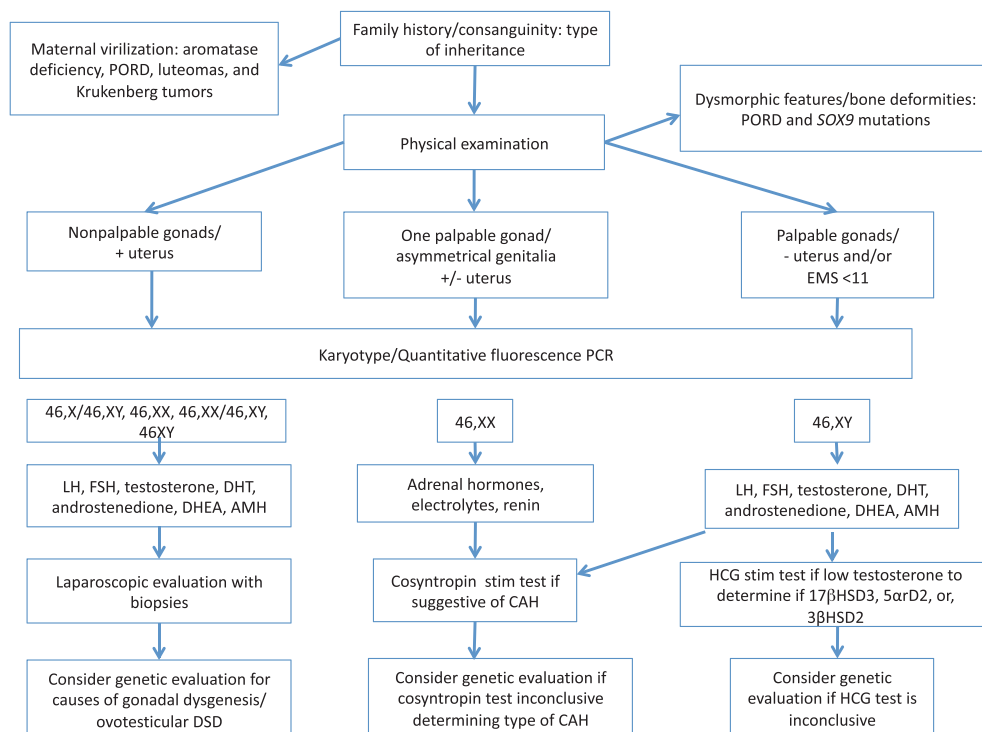


Figure 2. Pathway to evaluate patients with ambiguous genitalia. AMH=anti-müllerian hormone, 5 α -DHT=5 α -dihydrotestosterone, DSD=disorder of sex development, EMS=external masculinization score, FSH=follicle-stimulating hormone, HCG=human chorionic gonadotropin, LH=luteinizing hormone, PCR=polymerase chain reaction, PORD=P450 oxidoreductase deficiency.

simultaneously to identify any structural abnormality, chromosomal translocation, or mosaicism. (30)

Laboratory evaluation of individuals with 46,XY DSDs should include LH, FSH, DHEA, androstenedione, testosterone, 5 α -DHT, and AMH. Significant elevations of gonadotropin and testosterone levels are seen between 1 and 3 months of age. If testosterone levels are low, which usually occurs during the first month after birth and again after the fourth month after birth, an HCG stimulation test should be performed to clarify the diagnosis. A short protocol uses 1,500 IU of HCG intramuscularly on days 1, 3, and 5. If results are inconclusive with the short protocol, a long protocol using 1,500 IU intramuscularly every other day for a total of 7 injections is recommended. Samples taken at baseline and 48 hours after injection for DHEA, androstenedione, testosterone, and 5 α -DHT should be collected. For patients with a single dose of HCG, blood samples are collected 72 hours after the injection.

A low basal or post-HCG stimulation testosterone level is indicative of testicular dysgenesis or a testosterone biosynthesis defect. Normal or elevated levels of testosterone before and/or after HCG is suggestive of androgen insensitivity syndrome. The biochemical diagnosis of 5 α -RD2 deficiency in a prepubertal child is made when the ratio of

testosterone to 5 α -DHT is higher than 30 after HCG stimulation testing. However, a ratio of less than 30 does not rule out the condition; therefore, when this diagnosis is suspected, DNA sequencing of *SRD5A2* should be ordered.

A normal AMH level is a marker of normal Sertoli cell function; however, during the newborn period, in children with hypogonadotropic hypogonadism, and in patients with persistent müllerian duct syndrome due to AMH gene mutations, AMH levels may be low. (31) Inhibin B is another marker of Sertoli cell function that may be used with, or in place of, AMH.

Genetic analysis for mutations of the androgen receptor is recommended when a child has a DSD and normal testosterone production, proximal hypospadias, micropenis, and/or undescended testicles. However, 15% of individuals with CAIS, and 44% to 90% with apparent PAIS, are not found to have mutations of their androgen receptor. (31)

The use of array comparative genomic hybridization allows for the detection of chromosomal deletions or duplications below 5 Mb, clarifying the diagnosis in approximately 20% of individuals with DSDs. (32) To increase the odds of finding a genetic diagnosis in 46,XY individuals with DSDs, when ordering array comparative genomic hybridization it is

recommended to evaluate the most common genes associated with this condition: *AR*, *NR5A1*, *SRY*, *SRD5A2*, and *HSD17B3*. (31) The use of next-generation massive parallel targeted sequencing methods allows for the analysis of multiple genes that are known to be related to DSDs, and permits the evaluation of regulatory regions and microRNA, which cannot be detected using whole exome sequencing. (33) This technology also offers faster results than whole exome sequencing and whole genome sequencing. One problem with these tests is the interpretation of variants of uncertain significance in genes that are not known to be related to DSDs. (31)

Because CAH is the most common cause of DSDs in 46,XX individuals, evaluation of adrenal steroids, plasma renin activity, and electrolytes is essential. It is important to know that premature babies have higher levels of 17-OHP than term infants. If results are not conclusive, a cosyntropin stimulation test may be ordered after 48 hours of age. A dose of 0.25 or 0.125 mg in low-weight infants is used. Samples are obtained at baseline and 60 minutes after cosyntropin administration. To evaluate for the different causes of CAH, levels of 17-OHP, cortisol, 11-deoxycorticosterone, 11-deoxycortisol, 17-OH-pregnenolone, DHEA, and androsterone should be measured. In small children, to avoid taking a large volume of blood, the basal sample can be avoided. Evaluation of *CYP21A2* may avoid the need for a cosyntropin stimulation test; however, less common causes of CAH will be missed, and, therefore, a cosyntropin test is preferred.

Imaging Evaluation

Pelvic-labioscrotal ultrasonography is part of the initial evaluation of patients with ambiguous genitalia. Laparoscopic evaluation allows for better visualization of the gonads and internal structures, and for a biopsy of the gonads if considered necessary. However, laparoscopy is a more invasive procedure with possible complications.

Tumor Risk in Individuals with DSDs

Individuals with DSDs who carry Y chromosome material in their gonads are at increased risk for germ cell tumors, including gonadoblastomas, seminomas, and dysgerminomas. These tumors are seen in 30% of patients with gonadal dysgenesis, 17% with 17 β -HSD deficiency, 15% with PAIS, 2.6% with ovotesticular DSD, and 0.8% with CAIS. Among patients with *WT1* gene defects, malignancies have been reported in 60% with Frasier syndrome and 40% with Denys-Drash syndrome. (34)

TREATMENT

Gender Considerations

Gender assignment is a highly complex and controversial matter. In general, it is recommended to assign a gender to a child with a DSD after multidisciplinary team discussions, and in accordance with the family's wishes. Due to the possibility of developing gender dysphoria later in life, it is preferable to postpone genital surgery until the patient is old enough to have a thorough evaluation of his or her gender identity by a behavioral medicine specialist with expertise in this field. Furthermore, delaying genital surgery ensures that the patient is able to contribute to and participate in decisions about surgical procedures.

To avoid gender dysphoria and all of its potential detrimental consequences, it is vital to discuss both the importance of identifying early signs of gender dysphoria with the child's parents, and the critical value of familial support of the child's preferred, expressed gender.

Currently there are 5 main categories of DSDs in which gender assignment and, in some cases, surgical consideration for genital reconstruction, is necessary: 46,XX DSD, 46,XY DSD, sex chromosome mosaicism, ovotesticular DSD, and nonhormonal/nonchromosomal DSD. (25)

- Individuals categorized as having 46,XX DSD, most of whom have classic CAH, typically do not face gender assignment decisions and are raised female, unless there is severe masculinization, and male assignment can be considered.
- Patients who have 46,XY DSD are a clinically diverse group, encompassing abnormal androgen steroidogenesis such as 17 β -HSD3 and 5 α -RD2 deficiency. These individuals experience pubertal masculinization and when raised as male are very unlikely to change their gender. (13)(14)(25) If raised as females, due to the higher risk of changing their gender, pubertal blocking at the onset of puberty is recommended until gender identity is clear, and before performing any permanent surgery. (25) Patients with CAIS, or almost complete PAIS, should be raised as females.
- Sex chromosome mosaicism has several different manifestations. In patients with mixed gonadal dysgenesis or 45,X/46,XY DSD with asymmetrical genital features and mixed gonadal structures, questions of gender assignment, surgical timing, and possible gonadal removal due to tumor risk are difficult to answer. (25) Multidisciplinary team and family involvement are essential in determining sex assignment.
- Persons with ovotesticular DSD are also a diverse group. Their clinical presentation involves the presence of both ovarian and testicular tissues, which subsequently

makes for challenging decision making regarding gender assignment and genital surgery. (25) These conditions are further complicated by the likelihood of infertility. As with other DSD groups, choosing to delay a decision allows for individuals to participate in their own plan of care. Many seem to be more satisfied with their gender identity and sexual lives when they are raised as males. (25)

- In patients with nonhormonal/nonchromosomal DSD diagnoses, genitalia are significantly abnormal and internal organs are normal. Gender assignment and genital reconstruction are, therefore, also highly complex and challenging. (25) Historically, these patients were typically assigned as females, leading to a high prevalence of gender dysphoria. Therefore, assigning these patients as male is now considered preferable. (25)

Pharmacologic Treatment

Individuals with conditions associated with adrenal insufficiency should be treated with hydrocortisone at slightly suprphysiological doses three times a day, and with fludrocortisone if they also have mineralocorticoid deficiency. Salt supplementation is recommended in these patients to avoid higher fludrocortisone doses, which may induce hypertension.

Treatment with monthly injections of testosterone cypionate or enanthate for three or four doses has been used on infants with micropenis and suspected or documented PAIS to evaluate phallic enlargement. This is a method used by some clinicians to help determine gender assignment. If there is poor response to testosterone, female sex is assigned; if penile enlargement is significant, then male gender is assigned.

Hormone replacement in hypogonadism should be started at the time of puberty according to the assigned gender. Very low doses of estradiol via patches or oral micronized estradiol are commonly used in girls, and testosterone gels, patches, subcutaneous, or intramuscular injections have traditionally been used in boys. Progressive increments of the dose are used to reach adult hormone levels. In females, progesterone is added once they reach menarche, or after 2 years of treatment with estradiol. When no uterus is present, there is no need to use progesterone.

Surgery

The purpose of surgical treatment in patients with DSD is to make the genitalia as functional and normal-appearing as possible to allow intercourse, facilitate reproduction, reduce urologic complications, reduce risk of gonadal

tumors, and avoid psychosocial problems related to atypical anatomy. (25)

In 46,XX patients with classic CAH due to *CYP21A2* or *CYP11B1* mutations, traditionally, feminizing surgery was performed during infancy. Techniques for clitoral reduction with or without vaginal surgery have evolved during the past couple of decades, with positive functional results. Some teams prefer not to do surgery early in childhood, but later in life when the patient shows gender identity satisfaction. In cases of genital reconstruction during childhood, vaginal dilatation should be avoided until they become adolescents or young adults. (25)

Among 46,XY individuals with 5 α -RD2 and 17 β -HSD3 raised as females and identified as females before or during puberty, testes can be removed if gender identity is clear, or puberty can be blocked until gender is clarified because they will be become virilized during puberty. In patients with PAIS raised as males, orchiopexy should be performed early in life and gonads should be followed closely for early detection of tumor development by physical examination, ultrasonography, and tumor markers. For individuals with CAIS, due to the low risk of gonadal tumors and the positive effect in terms of feminization, gonads are retained at least until puberty. However, although the risk of tumors is low, it is difficult to have an effective method for monitoring undescended testes. (35)

Among 45,X/46,XY patients with Y material it is recommended to raise them as males despite the low chances of fertility and uncertain surgical outcomes. If male and female structures are present and female gender is considered, it is recommended to delay irreversible surgery until gender identity is established. (25) A streak gonad should be removed, considering the risk of developing tumors and the lack of function, and a scrotal gonad needs to be followed carefully. In individuals with ovotesticular DSD it is not recommended to remove genital structures until gender identity is clear.

THE MULTIDISCIPLINARY AND SHARED APPROACH

Children with ambiguous genitalia need early intervention to clarify their diagnosis, alleviate the anxiety that accompanies gender uncertainty, and, when necessary, begin lifesaving pharmacologic treatment. When ambiguous genitalia is identified, a multidisciplinary team approach, involving general pediatrics, neonatology, endocrinology, urology and/or surgery, genetics, radiology, nursing, and psychology, is of utmost importance. The general pediatrician or the pediatric endocrinologist should be the primary coordinator of care. The family should be educated that embryonic genital development is

complex, and be advised that obtaining a definitive diagnosis can take several days. Gender assignment should be postponed until additional information regarding diagnosis and treatment options are available. Shared decision making is essential, taking into account family cultural and religious preferences, as well as expectations and perceptions of sex and gender roles.

To avoid giving mixed or confusing information to the family, 1 member of the team should be delegated to communicate results and manage therapeutic decisions. Patient and family communication should occur frequently and in a calm environment with adequate time to address questions and concerns. Special attention should be given to the use of inoffensive terminology, and terms such as *differences* or *variations* in the genitalia should be used to avoid technical and intimidating language. For example, it can be said that “your child’s genitals look different than other girls or boys” or “some babies have variations of the common appearance of a child’s genitals.” The family needs to understand that the evaluation and management of these conditions is a long, ongoing process.

CONCLUSION

Despite dramatic advances in diagnostic genetic laboratory techniques over the past decade, many cases still lack a molecular diagnosis. Given the highly complex and dynamic conditions faced by these patients, there remains no consensus on DSD surgery regarding indications, timing, exact treatment, and outcome measures. Identification of centers of excellence that use a multidisciplinary approach to care is crucial. This approach mitigates the anxiety that families can experience and avoids the risks associated with rushed gender assignment decisions that may not consider probabilities of gender conformity/non-conformity later in life.

The ultimate goal of management is to optimize long-term quality of life by addressing issues related to anatomy, fertility, gender identity, physical and psychosocial development, and other physical, sexual, and mental health matters. This is best accomplished through ongoing, transparent communication between the team and the patients and their families, as well as

by supplying tailored referrals to support groups for caregivers and the affected individual. Support groups can play a vital role in education, advocacy, peer support, and even obtaining necessary medical and mental health care.

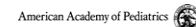
Summary

- Based on strong research evidence (evidence quality A), patients with gonadal dysgenesis and Y chromosome material should have a gonadectomy due to the high risk of gonadal neoplasia.(4)
- Based on strong research evidence (evidence quality A), the use of newborn screening permits early identification of 46,XX individuals with congenital adrenal hyperplasia and avoids life-threatening salt wasting. (15)
- Based on observational studies (evidence quality B), gender assignment among individuals with DSD is a complex process that should involve a multidisciplinary team and the family. (25)

**To view teaching slides that accompany this article, visit
<http://pedsinreview.aappublications.org/content/42/8/414>.**

Disorders of Sex Development
Alejandro Diaz, MD
Elizabeth G. Lipman Diaz, PhD, ARNP, CPNP

 Pediatrics in Review

 American Academy of Pediatrics
DEDICATED TO THE HEALTH OF ALL CHILDREN

References for this article can be found at
<http://pedsinreview.aappublications.org/content/42/No. 8/414>.



1. A term infant with a known prenatal karyotype of 46,XX is noted on physical examination shortly after birth to have moderate clitoromegaly and mild posterior labial fusion. The vagina and urethra have separate openings. There are no inguinal or labial masses. The infant has no other dysmorphic features. Pelvic ultrasonography shows normal internal female anatomy. The pregnancy and delivery were uncomplicated. Which of the following is the most likely cause of ambiguous genitalia in this infant?
 - A. Aromatase deficiency.
 - B. Androgen insensitivity syndrome.
 - C. Congenital adrenal hyperplasia:21 hydroxylase deficiency.
 - D. Mosaic Turner syndrome.
 - E. SRY loss-of-function mutation.

2. A term newborn infant is admitted to the nursery. The baby was the product of an uncomplicated pregnancy and delivery. Review of the prenatal records show that prenatal karyotyping was performed and revealed a 46,XY fetus. However, subsequent ultrasonography failed to identify a phallus. On physical examination, the infant has female-appearing external genitalia with a vaginal opening and bilateral inguinal masses. Pelvic ultrasonography of the infant disclosed absence of the uterus and ovaries and the presence of inguinal testicles. Which of the following is the most likely diagnosis in this patient?
 - A. Androgen insensitivity syndrome.
 - B. Congenital adrenal hyperplasia:21 hydroxylase deficiency.
 - C. Frasier syndrome.
 - D. Klinefelter syndrome.
 - E. Mayer-Rokitansky-Kuster-Hauser syndrome.

3. A term male infant has a midshaft hypospadias. The scrotum is empty and the gonads are palpated in the right and left inguinal canals. The stretched penile length is normal. The external masculinization score is 9. There are no additional dysmorphic features. The prenatal cell-free DNA testing of this infant disclosed a 46,XY karyotype. The most appropriate first step in the evaluation of this infant is to obtain which of the following studies?
 - A. Enhanced computed tomography of his abdomen.
 - B. Human chorionic gonadotropin stimulation test to measure testosterone levels.
 - C. Serum levels of insulinlike growth factor 1.
 - D. Sex chromosome evaluation and karyotype.
 - E. Whole genome sequencing.

REQUIREMENTS: Learners can take *Pediatrics in Review* quizzes and claim credit online only at: <http://pedsinreview.org>.

To successfully complete 2021 *Pediatrics in Review* articles for *AMA PRA Category 1 Credit*[™], learners must demonstrate a minimum performance level of 60% or higher on this assessment. If you score less than 60% on the assessment, you will be given additional opportunities to answer questions until an overall 60% or greater score is achieved.

This journal-based CME activity is available through Dec. 31, 2023, however, credit will be recorded in the year in which the learner completes the quiz.



2021 *Pediatrics in Review* is approved for a total of 30 Maintenance of Certification (MOC) Part 2 credits by the American Board of Pediatrics (ABP) through the AAP MOC Portfolio Program. *Pediatrics in Review* subscribers can claim up to 30 ABP MOC Part 2 points upon passing 30 quizzes (and claiming full credit for each quiz) per year. Subscribers can start claiming MOC credits as early as October 2021. To learn how to claim MOC points, go to: <https://www.aappublications.org/content/moc-credit>.

4. A term infant is born with ambiguous genitalia that precludes a gender assignment. The pediatric endocrinology and genetics services have been consulted. The medical students ask you about gender assignment. In general, which of the following is the most appropriate recommendation for these infants regarding their gender assignment?
- A. Always delay gender assignment until puberty to reflect the individual's gender identity and allow for their participation in decision making.
 - B. Assign female gender.
 - C. Assign male gender for those with a Y chromosome.
 - D. Gender assignment should be made expeditiously after birth.
 - E. Respect the family's decision about gender assignment after undergoing multidisciplinary team evaluation and counseling.
5. The infant metabolic screening test for a 9-day-old term girl is reported as positive for 3β -hydroxysteroid dehydrogenase/isomerase type 2 deficiency. The pregnancy and delivery were uncomplicated. The baby has been slow to feed at the breast. On physical examination, mild-to-moderate clitoromegaly is noted, and the remainder of the physical examination findings are normal. Blood samples that include measurement of steroid hormone levels and serum electrolyte levels are obtained. Which of the following is the most appropriate next step in the management of this infant?
- A. Obtain the results of confirmatory tests before requesting an endocrinology referral.
 - B. Initiate high-dose hydrocortisone treatment.
 - C. Initiate treatment with hydrocortisone, fludrocortisone, and salt supplementation.
 - D. Provide glucose water supplementation.
 - E. Provide potassium chloride supplementation.