

Acute Abdominal Pain

Robert D. Baker, MD, PhD*

*Department of Pediatrics, Digestive Disease and Nutrition Center, Jacobs School of Medicine and Biomedical Sciences, University at Buffalo, The State University of New York, Buffalo, NY

Education and Practice Gaps

Children frequently have acute abdominal pain. The physician must identify which child has a potentially catastrophic condition (<2%). Because the number of patients requiring immediate action is low, the physician can be lulled into a sense of safety. Infrequently, acute abdominal pain can be catastrophic, so the physician needs to be cognizant of conditions requiring action. Knowledge and judgment are key.

Objectives After completing this article, readers should be able to:

1. Understand the causes and frequency of acute abdominal pain in childhood.
2. Develop a differential diagnosis based on age and symptoms.
3. Formulate a plan for evaluation and management of acute abdominal pain.
4. Choose the appropriate imaging study for various diagnoses.

Acute abdominal pain is a frequent and challenging problem facing pediatricians. The cause of acute abdominal pain can range from John Apley's "little bellyacher" (1) to an emergency requiring immediate action. Assessing acute abdominal pain is a situation that requires excellent clinical acumen, an area where pediatricians should "prove their worth" by outperforming other primary caregivers. Making the correct diagnosis may earn the pediatrician accolades for saving a life (as in the case of intussusception or midgut volvulus) but may also not win friends (as when a mother is informed that the reason for her child's excruciating pain is constipation). A mistaken diagnosis can have devastating results, either by not acting when action is called for or by performing unnecessary tests and procedures.

Because the differential diagnosis list for acute abdominal pain is long, a logical approach is to consider diagnoses by age group. Convenient age divisions are neonates, 0 to 2 months; infants, 3 to 12 months; preschoolers, 1 to 5 years; children, 6 to 11 years; and adolescents, 12 to 18 years. Within each of these groups a diagnosis can be categorized as common or uncommon and as serious or less serious (Tables 1 through 5). (Note that designation as "serious" and "less serious"

AUTHOR DISCLOSURE Dr Baker has disclosed that he is a subinvestigator on PROKIDS (Pediatric Resource Organization for Kids with Inflammatory Intestinal Disease) and RISK (Pediatric Risk Stratification Study) grants. This commentary does not contain a discussion of an unapproved/investigative use of a commercial product/device.

ABBREVIATIONS

CRP	C-reactive protein
CT	computed tomography
DRE	digital rectal examination
ERCP	endoscopic retrograde cholangiopancreatography
GI	gastrointestinal
HIDA	hydroxyiminodiacetic acid
IV	intravenous
MRI	magnetic resonance imaging
TPN	total parenteral nutrition
WBC	white blood cell

TABLE 1. Causes of Acute Abdominal Pain in Neonates (Aged 0–2 Months)

	SERIOUS	LESS SERIOUS
Common	Necrotizing enterocolitis Adhesions	Colic
Uncommon	Volvulus Testicular torsion	Dietary protein allergy

is subjective but is based on whether immediate action is required. Diagnoses are not listed in order of frequency.)

Abdominal pain is perceived via mucosal or serosal receptors. These pain receptors are located on serosal surfaces, in the mesentery, and in the intestinal wall. Abdominal pain is poorly localized, often being perceived as midline, until the serosal surface becomes affected, as in appendicitis; then better localization occurs. (2) Children younger than 5 years are not able to localize pain well. A young child with acute otitis media may complain of abdominal pain.

For most children with acute abdominal pain, the pain is short, self-resolving, and non-life-threatening. In a study that included almost 1,000 children aged 4 to 18 years, close to 10% had at least 1 episode of acute abdominal pain that came to medical attention. Constipation accounted for 48% of these episodes, and 19% of the episodes went undiagnosed. Only 2% had a surgical cause for acute abdominal pain. (3) For the few that have conditions that require immediate action, age at onset, concomitant signs, symptoms, or history frequently lead to the correct disposition. For this reason, a detailed history, including history of the present condition, past medical history, and family history, and a complete physical examination (not just the abdomen) are essential. The digital rectal examination (DRE) has the potential to add important information regarding the cause of acute abdominal pain. A DRE can quickly establish the presence of constipation. Although constipation is a frequent cause of pain, the child with constipation may have acute abdominal pain due to unrelated causes. Frequently, laboratory investigation and imaging are performed. The results of these tests, along with age, history, and physical examination findings, weigh into the final conclusion. Coming to the correct disposition of a patient with acute abdominal pain relies on assembling available information and then judiciously considering the likely diagnoses.

APPENDICITIS

Appendicitis is the most common abdominal surgical emergency in childhood, although it is relatively uncommon in

children younger than 5 years (Tables 3 through 5). It can be rapidly progressive; from onset to perforation can be as short as 12 hours. Several scoring systems have been devised for the diagnosis of appendicitis in children. The 2 most widely used are the Alvarado score and the Pediatric Appendicitis Score. Both are based on similar parameters; however, the usefulness of both these scores has been questioned. (4) The scoring systems have been largely superseded by imaging studies that have changed the way in which appendicitis is diagnosed. The first is point of service ultrasonography. Ultrasonography has the obvious advantages of being readily available, being noninvasive, and avoiding radiation exposure. In the event that ultrasonography demonstrates appendicitis, it is highly specific. In a pediatric study, point of service ultrasonography confirmed a diagnosis in 51% of patients, thus avoiding computed tomography (CT). However, the usefulness of ultrasonography is limited, especially in obese children and in uncooperative children. Computed tomography remains the most accurate imaging study for diagnosing appendicitis. In many institutions it has become the imaging modality of choice. In one study it reduced the false-negative appendectomy rate from 23% to 1.7% in an 18-year period. At the conclusion of the study, essentially all of the patients who had surgery for appendicitis had a CT scan before surgery. (5) Because the radiation dose from a CT scan is high, efforts have concentrated on reducing the amount of radiation. A CT scan that uses lower levels of ionizing radiation and targeted CT scans have reduced radiation exposure. An avenue to eliminate radiation is the use of magnetic resonance imaging (MRI). As technology advances, MRI may become the imaging modality of choice; however, the time required for the study and the motion artifact are too great at present for routine use in diagnosing appendicitis. Serum markers, although nonspecific, can be of help. White blood cell (WBC) count with a left shift and C-reactive protein (CRP) level in combination have 94% specificity. Definitive management remains surgery.

INTUSSUSCEPTION

Intussusception refers to invagination of a proximal segment of bowel (the intussusceptum) into a distal segment (the intussusceps). The intussusceptum drags its mesentery with it into the distal bowel, leading to venous and lymphatic obstruction, ischemia, and perforation. This mechanism results in the classic triad of intermittent, severe abdominal pain, a sausage-shaped mass, and “currant jelly” stools. Especially early in the condition, intussusception can present with listlessness and a septiclike picture.

Intussusception can occur at any age, but it is the most common abdominal emergency in children 6 to 36 months of age (Tables 2 and 3). Within this age range, usually the terminal segment of the ileum invaginates into the cecum, creating an ileocolic intussusception. Peyer patches may act as the lead point of the intussusceptum. Hypertrophy of Peyer patches, as with viral illness or rotavirus vaccination, has been associated with intussusception. Other lead points are possible, especially outside the 6- to 36-month age range, including Meckel diverticulum, polyps, lymphoma, and duplications. Even after successful reduction of the intussusception, it is not unusual to have 1 or more recurrent episodes.

Because of improved diagnosis and treatment, the classic triad is now seldom seen. The more favorable outcome is most likely due to early diagnosis and more successful treatment. Ultrasonography has become the diagnostic method of choice, where the intussusception shows as a “target-shaped” finding. The specificity of ultrasonography approaches 100%. (6) Both CT and MRI are also excellent at visualizing an intussusception. Except in complicated or equivocal cases, there is seldom need to resort to these more complicated diagnostic imaging studies. However, the increased use of these studies in other situations has revealed that transient, self-resolving, asymptomatic small-bowel intussusceptions occur frequently and do not require treatment.

There are a variety of nonsurgical techniques for reducing an intussusception. These involve enemas (contrast, saline, or air) and some method of visualization (fluoroscopy or ultrasonography). Choice of technique is often institution dependent. However, the combination of warmed saline enemas and ultrasonography offers the advantage of excellent visualization along with avoidance of ionizing radiation. Chances of successfully reducing an intussusception depend on many factors, including the length of time that the symptoms have been present, the age of the patient, whether there is a lead point, and the location of the intussusception. If a reduction attempt is only partially successful and the patient remains stable, at least 3 nonsurgical reductions can be tried before resorting to surgery. The unstable patient should go directly to surgery. Nonsurgical reduction is successful approximately 80% of the time. Perforation occurs in less than 1% of patients during nonsurgical reductions. (7)

CHOLECYSTITIS, CHOLELITHIASIS, CHOLEDOCHOLITHIASIS

Gallbladder disease in children is being diagnosed and treated with increased frequency. This increase is partly

TABLE 2. Causes of Acute Abdominal Pain in Infants (Aged 3–12 Months)

	SERIOUS	LESS SERIOUS
Common	Foreign body ingestion Trauma	Constipation Gastroenteritis Viral illness Dietary protein allergy Urinary tract infection
Uncommon	Adhesions Hemolytic uremic syndrome Hirschsprung disease Intussusception Incarcerated hernia Sickle cell crisis Tumor	Hepatitis

due to greater awareness and partly to the epidemic of childhood obesity (Tables 4 and 5). Cholelithiasis and gallbladder sludge was documented in 2.36% of children undergoing abdominal ultrasonography for any reason. (8) Factors that are known to predispose to gallbladder disease include total parenteral nutrition (TPN), hemolytic diseases, systemic infections, some antibiotics, biliary anatomical anomalies, cystic fibrosis, increased estrogen (pregnancy or oral contraception), a positive family history, and obesity. Interruption of the enterohepatic circulation can lead to gallstone formation, as in Crohn disease with ileal involvement and short small bowel with ileal resection. There is a racial (Amerindian) and a genetic predisposition to the development of gallstones. The composition of gallstones in children is different from that in adults. Classically, gallstones have been categorized as cholesterol stones

TABLE 3. Causes of Acute Abdominal Pain in Preschoolers (Aged 1–5 Years)

	SERIOUS	LESS SERIOUS
Common	Appendicitis Foreign body ingestion Intussusception Trauma	Constipation Viral illness Gastroenteritis Pharyngitis Urinary tract infection Pneumonia
Uncommon	Adhesions Hemolytic uremic syndrome Intra-abdominal abscess Diabetic ketoacidosis Ovarian torsion Sickle cell crisis Tumor	Henoch-Schönlein purpura Hepatitis

TABLE 4. Causes of Acute Abdominal Pain in Children (Aged 6–11 Years)

	SERIOUS	LESS SERIOUS
Common	Adhesions Appendicitis Diabetic ketoacidosis Inflammatory bowel disease Trauma	Constipation Viral illness Gastroenteritis Pharyngitis Urinary tract infection Pneumonia
Uncommon	Hemolytic uremic syndrome Perforated ulcer Primary bacterial peritonitis Hemolytic uremic syndrome Intra-abdominal abscess Myocarditis/pericarditis Pancreatitis Ovarian/testicular torsion Sickle cell crisis Tumor	Abdominal migraine Cholecystitis Henoch-Schönlein purpura Hepatitis Familial Mediterranean fever

and pigmented stones. Pigmented stones are subdivided into black stones and brown stones. Gallstones are seldom, if ever, pure. Cholesterol stones (which predominate in adults) are composed of only 50% cholesterol. The remainder is made up of glycoprotein and calcium salts.

TABLE 5. Causes of Acute Abdominal Pain in Adolescents (Aged 12–18 Years)

	SERIOUS	LESS SERIOUS
Common	Adhesions Appendicitis Diabetic ketoacidosis Inflammatory bowel disease Hemolytic uremic syndrome Pelvic inflammatory disease Trauma	Constipation Viral illness Gastroenteritis Pharyngitis Urinary tract infection Dysmenorrhea Pneumonia Ruptured ovarian cyst
Uncommon	Hemolytic uremic syndrome Perforated ulcer Primary bacterial peritonitis Intra-abdominal abscess Myocarditis/pericarditis Pancreatitis Sickle cell crisis Ovarian/testicular torsion Ectopic pregnancy Tumor	Abdominal migraine Cholecystitis Henoch-Schönlein purpura Hepatitis Familial Mediterranean fever Urolithiasis

Cholesterol stones are associated with obesity and cystic fibrosis and are less frequent in children than in adults. Black pigment stones are more common in children than in adults and are associated with hemolytic disease and TPN. Calcium carbonate stones (associated with systemic disease) and brown pigment stones (associated with bacterial infection) can occur in children. The presentation of cholelithiasis and cholecystitis in children is variable and less specific than the presentation in adults. Although in adults the combination of right upper quadrant pain with vomiting exacerbated by eating fatty food is suggestive of cholelithiasis, children may present with merely nonspecific, poorly localized pain. The classic presentation of cholecystitis in adults of right upper quadrant pain, vomiting, fever, and leukocytosis may not be present in children or may be obscured by other findings. Although biliary pain is described as “constant” by both adults and children.

The evaluation of a child suspected of having gallbladder disease should include a WBC count, inflammatory markers (erythrocyte sedimentation rate and CRP), liver function tests, amylase, and lipase. Imaging should be performed in any child with a suggestive history and/or physical examination findings, even if the laboratory test results are normal. Abdominal ultrasonography has a better than 90% accuracy for diagnosing cholelithiasis, (9) where stones show up as movable masses (in contradistinction to gallbladder polyps) of variable size. On ultrasonography, gallstones cast “shadows” that are pathognomonic. Gallbladder sludge is a frequent incidental finding on abdominal ultrasonography (1.46% of abdominal ultrasonography in children [8]). The significance of sludge is not clear. Some believe that sludge is a precursor to stones, and others believe that it has no long-term significance. Gallbladder wall thickening indicative of cholecystitis is less specific and can occur in hepatitis and with generalized edema. Gallbladder wall thickening should be interpreted in the context of other findings. Abdominal ultrasonography can assess intrahepatic and extrahepatic ducts, pancreas, and adjacent structures. HIDA scans are as accurate as ultrasonography in diagnosing cholecystitis. HIDA stands for hydroxyiminodiacetic acid, a radiopharmaceutical tracer that is no longer used for the scan, but the name has remained. A HIDA scan is performed by administering the radiotracer intravenously. The tracer is taken up by the liver and excreted via the biliary ducts. It shows up in the gallbladder within 1 to 4 hours. From a practical point of view, HIDA scans are not used for the diagnosis of cholecystitis because they require advanced planning and are not readily available. The HIDA scan does measure gallbladder excretion. Biliary

dyskinesia (delayed gallbladder excretion demonstrated by HIDA scan) may be an uncommon cause of abdominal pain in children. Many children who undergo cholecystectomy for a decreased ejection fraction have postoperative recurrence of symptoms, bringing into question whether the gallbladder dysfunction was the true cause of the pain. (10) Endoscopic retrograde cholangiopancreatography (ERCP) is diagnostically useful in older children and teenagers. It has the distinct advantage that it can be therapeutic for common duct stones. (It can remove stones in bile ducts, stretch bile duct strictures, and place stents across a strictured area.) It is seldom performed in young children because the endoscopes are too large and pediatric endoscopists lack the skill to perform this procedure. Postprocedure pancreatitis is not uncommon. Magnetic resonance cholangiopancreatography has become increasingly useful in complicated biliary disease as the quality and resolution of the technique has improved. It is as sensitive, perhaps more sensitive, than ultrasonography for the diagnosis of cholecystitis. It avoids radiation but usually requires sedation. It is not universally available.

Management of gallbladder disease varies with the age of the patient and the type of disease. In neonates with stones and no cholecystitis, symptomatic management and observation is usually adequate. Resolution without intervention can be expected. Resolution of stones associated with TPN may occur spontaneously. In older children the stones are unlikely to resolve without treatment. Autopsy data show that many people live and die with gallstones that never became symptomatic. For those found to have asymptomatic gallstones, elective removal is safe and simple, so cholecystectomy is a reasonable option in those who are at high risk for developing symptoms. Cholecystectomy for gallstones in hemolytic diseases, such as sickle cell disease and spherocytosis, is mandatory. Definitive surgery can usually be performed as an elective procedure.

Acute cholecystitis presents a more critical and more dangerous scenario. Presentation is characterized by severe right upper quadrant pain, sometimes radiating to the back. Vomiting is often present. Fever and jaundice occur in approximately one-third of affected children. Inflammation of the gallbladder adjacent to the serosa gives rise to a Murphy sign, which is severe, sharp pain with cessation of breathing on palpation of the right upper quadrant. Children with acute cholecystitis should be hospitalized, made nil per os, and administered intravenous fluids and pain medications. Consideration of intravenous antibiotics should be given, especially in the face of persistent fever. Laparoscopic removal of the gallbladder should occur when the child is stabilized.

PANCREATITIS

The apparent incidence of acute pancreatitis in children is rising; however, it is not clear whether this is a true increase or more awareness. In the United States, a rate of 13.2 cases per 100,000 children per year is reported, whereas only 3.6 cases per 100,000 children per year are reported in Australia (Table 5). (11)(12) Pancreatitis in adults and children probably share the same final pathway, but the initiating events differ. Gallstones and alcohol are the common underlying factors in pancreatitis in adults. In children, for one-third of cases no etiology is found. Systemic illness, biliary diseases, medications, trauma, and suspected infection account for most underlying etiologies. In addition, only 10% of childhood pancreatitis will progress to recurrent or chronic pancreatitis.

Any of the underlying etiologies mentioned (and perhaps others) can lead to pathologic activation of calcium signaling in the acinar cells of the pancreas that triggers intracellular activation of proteases. Predominantly, trypsinogen is converted to the active trypsin. This cascade leads to cytokine release, inflammation, edema, and cell destruction. Mechanisms to counteract pancreatic damage are pancreatic enzyme compartmentalization, trypsin autodegradation, and trypsin inhibition, including activation of serine protease inhibitor Kazal type 1 (SPINK1).

The diagnosis of acute pancreatitis is based on presentation, biochemical profile, and imaging. The International Study Group of Pediatric Pancreatitis: In Search for a Cure (INSPPIRE) listed guidelines for diagnosis, which include clinical findings of abdominal or back pain, nausea and vomiting, amylase or lipase levels greater than 3 times the upper limit of normal, and imaging findings consistent with pancreatitis. (13) Care must be exercised when eliciting and interpreting clinical findings. Epigastric pain is the most common finding, but diffuse abdominal pain is not uncommon in children. Infants and toddlers frequently do not have abdominal pain but frequently have fever and abdominal distention. Back pain, despite the fact that it is one of the classic symptoms, is rare. Likewise, ecchymosis of the flank (Grey sign) is almost never present. Nonverbal patients may not be able to indicate abdominal pain and may well be taking medications known to be associated with pancreatitis, such as valproic acid.

The imaging study of choice is controversial. Ultrasonography is almost always the first imaging study performed because it is readily available, avoids radiation, and gives information about the pancreas and about surrounding structures and other causes of pain. It is the best test to identify stones. However, obesity and bowel gas can limit assessment of the pancreas itself. The CT scan gives different information. It is the best test for assessing the complications of pancreatitis, such as hemorrhage,

necrosis, and pseudocyst formation. (14) For this reason, it is frequently performed several days into treatment, when complications are suspected. There is not sufficient information on MRI for acute pancreatitis; however, with improving technology, it may become an option.

Other imaging studies used to further delineate causes of pancreatitis, such as magnetic resonance cholangiopancreatography, endoscopic ultrasonography, and ERCP, do not play a role in the diagnosis and treatment of acute pancreatitis except that ERCP is curative for pancreatitis due to a stone obstructing the common duct. In trauma-induced pancreatitis, ERCP can demonstrate the extent of ductal damage.

The treatment of acute pancreatitis consists of 3 elements: 1) pain management, 2) fluid management, and 3) nutrition. Morphine is the most widely used pain medication for acute pancreatitis in children, despite the concern that morphine might induce sphincter of Oddi spasm, thus worsening the pancreatitis. Narcotic-sparing medication and nerve blocks have been tried in adults, but there is no experience in children. Fluid therapy should be early and aggressive. During the first 24 hours, 2 to 3 times maintenance fluids should be administered. In the past, patients with acute pancreatitis were allowed nothing by mouth and often had a nasogastric tube placed and stomach contents suctioned. Patients often received intravenous nutrition. More recent studies have demonstrated that there is no need to avoid using the gastrointestinal (GI) tract for nutrition. Children with mild pancreatitis can be allowed a low-fat diet from the beginning of therapy. In more severe cases, nasogastric or nasojejunal feeding can be instituted within the first few days.

Antibiotics are not recommended as a routine therapy, even in severe pancreatitis; however, if superinfection is suspected, cultures should be obtained and broad spectrum antibiotics used until culture results can allow narrowing the antibiotic coverage.

For adults with acute pancreatitis, there are several scoring systems to predict the severity of the disease, including the Ranson criteria, the modified Glasgow scale, and the Apache II index. None of these are applicable to pediatric disease. In fact, there is no clear definition of what constitutes severe acute pancreatitis in a child. (15)

MALROTATION AND VOLVULUS

Midgut volvulus is a true surgical emergency. The time from the first signs of obstruction to necrotic bowel requiring resection can be a few hours. If resection of necrotic bowel becomes necessary, the bowel removed can include the small bowel from the duodenojejunal junction to the mid-transverse colon, including the ileocecal valve and cecum (the distribution of the superior mesenteric artery).

A child who undergoes surgery of this extent will have extreme short bowel syndrome and interruption of the enterohepatic circulation. With only a few centimeters of small bowel remaining, the child will almost certainly be dependent on parenteral nutrition, and there is a high probability that a small-bowel transplant will become necessary. Small-bowel volvulus commonly (45%) occurs in the context of intestinal malrotation. Malrotation is the failure of the normal rotation and fixation of the bowel during organogenesis. The result is a cecum that is free to fold and unfold on itself, usually in the right upper quadrant. This folding and unfolding can lead to intermittent symptoms of obstruction and pain. Ladd bands extend from the cecum to the abdominal wall, crossing the duodenum. There can be duodenal obstruction from these bands. In malrotation, the small bowel is located on the right side of the abdomen, resulting in a narrow mesenteric root. This allows the intestine to twist around the mesentery, compromising the superior mesenteric artery with subsequent ischemia and bowel death. Volvulus of the small bowel can be due to adhesions or bands (30%), Meckel's diverticulum, or idiopathic. (16) Rotational abnormalities are thought to be present in 1 of 100 to 1 of 3,000 live births. However, the true incidence is not known because many are asymptomatic. Of the intestinal rotation abnormalities that come to medical attention, half will be found before a month of age and 90% will be diagnosed before a year (Table 1). However, midgut volvulus can occur at any age, so most surgeons will perform the Ladd procedure to alleviate intestinal malrotation when an incidental malrotation is discovered.

The diagnosis of small-bowel volvulus depends on a high index of suspicion. The most consistent finding is bilious and nonbilious vomiting. Abdominal distention may or may not be present. Abdominal pain is an inconsistent symptom. Laboratory abnormalities are not specific to volvulus but include leukocytosis, elevated CRP levels, and hyponatremia. The imaging study of choice is the contrast upper GI series, which is 96% sensitive and demonstrates abnormal positioning of the third and fourth portion of the duodenum in malrotation and the "corkscrew" sign when midgut volvulus is present. Ultrasonography has not replaced the upper GI series, although the midgut volvulus findings on ultrasonography include the "whirlpool" sign and inversion of the superior mesenteric artery and vein, with the superior mesenteric vein on the left anterior side of the superior mesenteric artery instead of its usual right side location. These ultrasonography findings are not as consistent as the upper GI series findings. (17)

Management of midgut volvulus is to proceed to corrective surgery as quickly as feasible. Initial therapy includes fluid resuscitation, evacuation of the stomach via nasogastric suctions, and broad spectrum antibiotics followed by definitive surgery. In one series, the resection rate was

44.9%, and 14.3% had postoperative complications, including short bowel syndrome, adhesions, intra-abdominal abscess, and failure to thrive. (16)

CONSTIPATION

Constipation is the most frequently identified cause of acute abdominal pain. It is not a medical emergency, but it often presents as such. Importantly, constipation causing a picture of acute abdominal pain almost certainly has been present for months, if not years. A careful history will reveal that such a child with constipation has a long history of difficulty defecating, with infrequent bowel movements. Bowel movements may be large and hard or small and pebbly. The bowel movements may be painful, and withholding behavior may be present. A history of daily soft-to-loose bowel movements does not exclude the possibility of constipation because constipation with overflow may be present. Physical examination may reveal multiple fecal masses felt through the abdominal wall; sometimes a single, large mass is palpable in the suprapubic area. A DRE may reveal hard stool in the rectal vault, or the vault may be empty, as in the case of Hirschsprung disease. Constipation has many etiologies (Table 6), but by far the most common is functional constipation, which is present in 0.7% to 29.6% of children. (18) Functional constipation is defined by the Rome III criteria; (19) however, just as useful is the working definition “infrequent passage of hard, uncomfortable stools that are distressing to the child.” (20)

Acute abdominal pain caused by constipation is due to retention of fecal material anywhere in the colon. The pain is poorly localized, usually nonradiating. Mild tenderness to palpation is commonly present. History and physical examination should suggest constipation, but laboratory investigation and

imaging are frequently necessary to exclude other diagnoses. In the constipated child, WBC count, CRP level, and electrolyte levels will be normal. Ultrasonography will not demonstrate appendicitis. The usefulness of an abdominal radiograph to diagnose constipation is questionable, (21) but it may be useful as a baseline in determining the results of treatment.

In the absence of obstruction (constipation rarely, if ever, causes complete obstruction), the current recommendation for acute abdominal pain due to constipation is to administer large-volume osmotic laxatives (lactulose or polyethylene glycol 3350) enterally, by mouth, or by nasogastric tube. Enemas are not recommended because they will not cleanse the entire colon and are not well tolerated. An abdominal radiograph can ensure that the colon is substantially free of fecal material. If not, a repeated colon cleanse is required. After evacuation of the colon, a maintenance regimen of daily stool softeners, daily toilet sitting, and improved diet is initiated.

CONCLUSION

Acute abdominal pain in childhood is a frequent and challenging clinical symptom. The diagnoses are many and vary in severity, evaluation, and outcome. The clinician must exercise acumen to arrive at the correct diagnosis and must remain vigilant to identify the child who requires immediate treatment.

Summary

- Acute abdominal pain is a common occurrence. One in a hundred children will experience at least 1 episode of acute abdominal pain that will come to medical attention. However, most episodes are not emergencies. It is the rare episode that requires immediate and accurate action. (3) (Strength of evidence C. Observational study.)
- Acute appendicitis remains the most common surgical emergency in pediatrics. Although serum markers are helpful, imaging, in particular point of service ultrasonography and targeted computed tomography (CT), has reduced the false-negative appendectomies to less than 2%. (5) (Strength of evidence C. Observational study.)
- Improved imaging has changed the course of a child with intussusception. Ultrasonography is close to 100% accurate, resulting in much earlier diagnosis. Incidentally, abdominal CT scanning and magnetic resonance imaging (MRI) have demonstrated that minor small bowel to small bowel intussusceptions occur frequently and are self-resolving. (6) (Strength of evidence D. Expert opinion and review of the literature.)
- Gallstones and gallbladder sludge are frequent findings on abdominal ultrasonographic images and may not be the cause of abdominal pain. (8) (Strength of evidence C. Observational study.)

TABLE 6. Reasons for Defecation Difficulty

Functional constipation	Infant dyschezia
Hypothyroidism, hypercalcemia, hypokalemia	Imperforate anus, anal stenosis
Celiac disease	Dietary protein allergy
Diabetes mellitus	Hirschsprung disease
Spinal cord anomalies, tethered cord	Cystic fibrosis
Opioids, anticholinergics, antidepressants	Abnormal abdominal wall, prune belly
Heavy metal ingestion (lead)	Gastroschisis, trisomy 21
Sexual abuse	Botulism
Vitamin D intoxication	

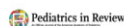
- Cholecystitis has a less specific presentation in children than in adults. Although laboratory tests are helpful, ultrasonography is better than 90% accurate; imaging should be performed in any child with a suggestive history or physical examination findings. (9) (Strength of evidence B. Prospective diagnostic study.)
- Delayed gallbladder ejection demonstrated by HIDA scan may be an uncommon cause of acute abdominal pain in children. However, many children who undergo cholecystectomy for this reason have recurrence of their pain. (10) (Strength of evidence D. Expert opinion and review of the literature.)
- Pancreatitis in children is being diagnosed more frequently than in the past. In most children, the pancreatitis will not become chronic. (11) (Strength of evidence C. Observational study.)
- Ultrasonography is the imaging modality of choice for yielding information about the pancreas and surrounding tissues. However, CT and MRI are superior to ultrasonography for assessing complications of pancreatitis (14) (Strength of evidence C. Observational study.)
- Malrotation almost always occurs in neonates or infants, but it can occur at any age. Half the cases of malrotation require resection, and in those resected, complications, mainly short bowel syndrome, are common. (16) (Strength of evidence C. Observational study.)

- Constipation is the most frequently identified cause of acute abdominal pain in children. Estimates of the overall frequency of constipation in childhood are as high as 29%. Diagnosis is suggested by history and physical examination findings. (3) (Strength of evidence C. Observational study.)

To view teaching slides that accompany this article, visit <http://pedsinreview.aappublications.org/content/39/3/130.supplemental>.

Acute Abdominal Pain

Robert D. Baker, MD, PhD



References for this article are at <http://pedsinreview.aappublications.org/content/39/3/130>.

PIR Quiz

There are two ways to access the journal CME quizzes:

1. Individual CME quizzes are available via a handy blue CME link under the article title in the Table of Contents of any issue.
2. To access all CME articles, click "Journal CME" from Gateway's orange main menu or go directly to: <http://www.aappublications.org/content/journal-cme>.
3. To learn how to claim MOC points, go to: <http://www.aappublications.org/content/moc-credit>.

1. A 10-year-old boy presents to the emergency department with abdominal pain of 8 hours' duration and vomiting that began approximately 4 hours ago. He has not had any diarrhea. The pain is constant and severe, with no variation. Physical examination reveals a temperature of 100.8°F (38.2°C). Abdominal examination shows marked abdominal tenderness localized over the right lower quadrant. There is obvious rebound tenderness noted. Bowel sounds are absent. Which of the following is the most appropriate imaging study to perform as a next step to confirm the diagnosis in this patient?
 - A. Computed tomographic (CT) scan of the abdomen.
 - B. Endoscopic retrograde cholangiopancreatography.
 - C. Magnetic resonance cholangiopancreatography.
 - D. Magnetic resonance imaging (MRI) of the abdomen.
 - E. Ultrasonography of the abdomen.
2. A 2-year-old boy presents with intermittent abdominal pain that started approximately 10 hours ago. He has attempted to eat and drink but has had several episodes of vomiting. There is no diarrhea or fever. The pain appears every 15 to 20 minutes and lasts for approximately 1 to 2 minutes. Between episodes the child is in no distress and in fact seems to be playful. Physical examination reveals a playful child with a soft, mildly tender abdomen. As you start to leave the room, the patient screams in pain and once again holds his abdomen. Under which of the following circumstances is immediate surgical intervention indicated as the best management option for this condition?
 - A. Failure of morphine to resolve the pain.
 - B. Gross blood in the stool.
 - C. Patient older than 1 year.
 - D. Recurrence of symptoms 10 minutes after a reduction attempt.
 - E. The patient is hypotensive and tachycardic.
3. A 10-year-old obese girl has had intermittent colicky right upper quadrant abdominal pain exacerbated by meals for 2 to 3 weeks. There has been intermittent vomiting, but no fever or diarrhea. The patient is healthy, has no underlying chronic medical problems, and is taking no medications. Abdominal ultrasonography shows multiple shadows in the gallbladder. Which of the following is the most likely cause of the shadows in the gallbladder of this patient?
 - A. Black pigment stones.
 - B. Brown pigment stones.
 - C. Calcium carbonate stones.
 - D. Cholesterol stones.
 - E. Clumps of white blood cells.
4. A 12-year-old obese boy with recently diagnosed gallstones presents with fever, vomiting, and severe back pain. There is no dysuria or diarrhea. Examination reveals a child in moderate distress with epigastric abdominal tenderness and back tenderness. His serum lipase level is elevated 4 times above the upper limit of normal, and ultrasonography shows inflammation in the pancreas and a small, radiodense object in the pancreatic duct. Which of the following is the next best step in the management of this patient?

REQUIREMENTS: Learners can take *Pediatrics in Review* quizzes and claim credit online only at: <http://pedsinreview.org>.

To successfully complete 2018 *Pediatrics in Review* articles for *AMA PRA Category 1 Credit™*, learners must demonstrate a minimum performance level of 60% or higher on this assessment. If you score less than 60% on the assessment, you will be given additional opportunities to answer questions until an overall 60% or greater score is achieved.

This journal-based CME activity is available through Dec. 31, 2020, however, credit will be recorded in the year in which the learner completes the quiz.



2018 *Pediatrics in Review* now is approved for a total of 30 Maintenance of Certification (MOC) Part 2 credits by the American Board of Pediatrics through the AAP MOC Portfolio Program. Complete the first 10 issues or a total of 30 quizzes of journal CME credits, achieve a 60% passing score on each, and start claiming MOC credits as early as October 2018. To learn how to claim MOC points, go to: <http://www.aappublications.org/content/moc-credit>.

- A. Place a nasogastric tube to low suction and keep the patient nothing by mouth for at least 1 week.
 - B. Restrict intravenous fluids to two-thirds maintenance rate.
 - C. Start broad spectrum antibiotics to provide gram-negative coverage.
 - D. Start the patient on a diet high in fats within 24 hours.
 - E. Treat the pain with frequent doses of morphine.
5. A 3-week-old boy is brought to the emergency department with abdominal pain and distention that began 4 hours earlier. He has had several episodes of bilious vomiting. There is no diarrhea. On physical examination, his abdomen is distended and quite tender. He is in obvious distress. Which of the following is the imaging study of choice to confirm the most likely diagnosis in this patient?
- A. Contrast upper gastrointestinal series.
 - B. CT of the abdomen.
 - C. MRI of the abdomen.
 - D. Plain abdominal radiograph.
 - E. Ultrasonography of the abdomen.

Acute Abdominal Pain
Robert D. Baker
Pediatrics in Review 2018;39;130
DOI: 10.1542/pir.2017-0089

Updated Information & Services	including high resolution figures, can be found at: http://pedsinreview.aappublications.org/content/39/3/130
Supplementary Material	Supplementary material can be found at: http://pedsinreview.aappublications.org/content/suppl/2018/02/28/39.3.130.DC1
References	This article cites 21 articles, 2 of which you can access for free at: http://pedsinreview.aappublications.org/content/39/3/130.full#ref-list-1
Subspecialty Collections	This article, along with others on similar topics, appears in the following collection(s): Medical Education http://classic.pedsinreview.aappublications.org/cgi/collection/medical_education_sub Journal CME http://classic.pedsinreview.aappublications.org/cgi/collection/journal_cme Gastroenterology http://classic.pedsinreview.aappublications.org/cgi/collection/gastroenterology_sub Abdominal Pain http://classic.pedsinreview.aappublications.org/cgi/collection/abdominal_pain_sub
Permissions & Licensing	Information about reproducing this article in parts (figures, tables) or in its entirety can be found online at: https://shop.aap.org/licensing-permissions/
Reprints	Information about ordering reprints can be found online: http://classic.pedsinreview.aappublications.org/content/reprints



Acute Abdominal Pain

Robert D. Baker

Pediatrics in Review 2018;39;130

DOI: 10.1542/pir.2017-0089

The online version of this article, along with updated information and services, is located on the World Wide Web at:

<http://pedsinreview.aappublications.org/content/39/3/130>

Pediatrics in Review is the official journal of the American Academy of Pediatrics. A monthly publication, it has been published continuously since 1979. Pediatrics in Review is owned, published, and trademarked by the American Academy of Pediatrics, 345 Park Avenue, Itasca, Illinois, 60143. Copyright © 2018 by the American Academy of Pediatrics. All rights reserved. Print ISSN: 0191-9601.

American Academy of Pediatrics

DEDICATED TO THE HEALTH OF ALL CHILDREN®

