

# Pediatric Solid Tumors of Infancy: An Overview

Wendy Allen-Rhoades, MD, FAAP,\* Sarah B. Whittle, MD, MS, FAAP,\* Nino Rainusso, MD, FAAP\*

\*Department of Pediatrics, Section of Hematology-Oncology, Baylor College of Medicine and Texas Children's Hospital Cancer and Hematology Centers, Houston, TX

## Practice Gaps

Pediatricians should recognize the role of age, genetic factors, and syndromes that predispose to the development of certain pediatric solid tumors. Many symptoms of common childhood illnesses that progress or do not resolve in a timely manner should require a detailed evaluation and prompt referral to a cancer specialist.

## Objectives After completing this article, readers should be able to:

1. Recognize the presenting signs and symptoms of pediatric solid tumors (eg, abdominal mass, constipation, shortness of breath, back pain, bone pain, fever, and hypertension).
2. Identify the signs and symptoms of retinoblastoma, neuroblastoma, hepatoblastoma, and Wilms tumor.
3. Recommend genetic evaluation and close disease surveillance for patients with certain solid tumors or particular predisposing conditions.
4. Recognize general aspects of the multidisciplinary treatment approach in children with retinoblastoma, neuroblastoma, hepatoblastoma, and Wilms tumor.

**AUTHOR DISCLOSURE** Drs Allen-Rhoades and Whittle have disclosed no financial relationships relevant to this article. Dr Rainusso has disclosed that he has received a career development award grant from St Baldrick's Foundation and a sarcoma scholar grant from Snowdrop Foundation. This commentary does not contain a discussion of an unapproved/investigative use of a commercial product/device.

### ABBREVIATIONS

AFP	$\alpha$ -fetoprotein
ASCT	autologous stem cell transplant
CT	computed tomography
FDA	Food and Drug Administration
MRI	magnetic resonance imaging
OMS	opsoclonus myoclonus syndrome
VIP	vasoactive intestinal peptide
<sup>123</sup> I-MIBG	<sup>123</sup> I-meta-iodo-benzylguanidine

## INTRODUCTION

Pediatric solid tumors are a group of nonhematologic, extracranial cancers that occur during childhood. This heterogeneous group of tumors represents approximately 40% of all pediatric cancers (Fig 1). Many pediatric solid tumors are referred to as embryonal or developmental cancers because they arise in young children or adolescents as a result of alterations in the processes of organogenesis or normal growth. In this review, we address common symptoms developed in children diagnosed as having malignant solid tumors and offer a general description of the most common pediatric solid tumors in infants and young children. Common malignant solid tumors in adolescents will be addressed in a separate article.

## PRESENTING SYMPTOMS OF PEDIATRIC SOLID TUMORS

The rarity of solid tumors combined with a variety of symptoms observed across different tumor types renders timely diagnosis of these conditions difficult.

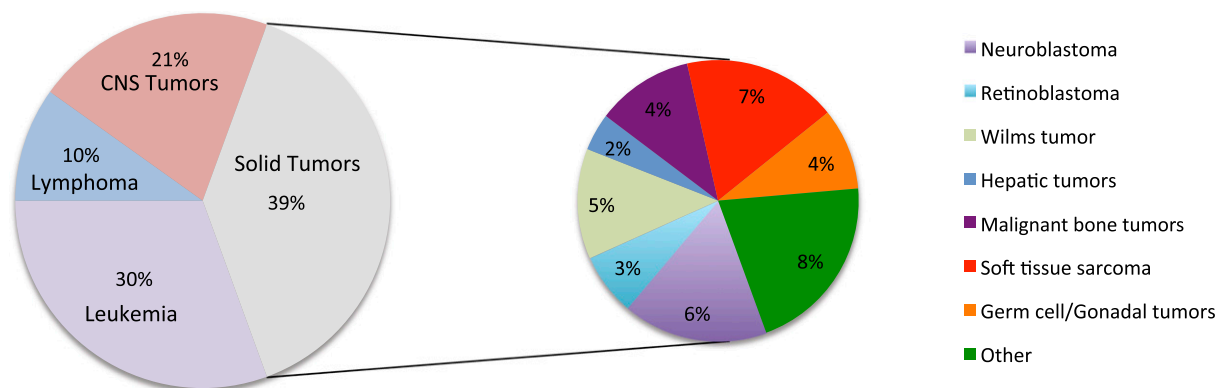


Figure 1. Percentage distribution of pediatric cancers and solid tumors in children (0–14 years old).

Many presenting signs and symptoms of pediatric solid tumors mimic those of common childhood illnesses, which makes it critically important for primary care providers to consider malignancy in their differential diagnoses and to understand indications for further diagnostic evaluation to rule out a solid malignancy in a child or adolescent. The age of the patient can be helpful in the differential diagnosis of any mass identified on physical examination (Table).

### Abdominal Masses

One of the most common presenting signs of solid tumors in children is a palpable abdominal mass. Often, the mass is brought to the attention of the primary care provider by a parent or guardian. Although there are a variety of benign

abdominal masses, all abdominal masses require further diagnostic evaluation. Most malignant abdominal masses are found in children ages 1 to 5 years, with Wilms tumor and neuroblastoma being the most common. Children with Wilms tumor often appear well aside from the palpable mass but may have urinary symptoms such as hematuria, frequency, or incontinence. Children with neuroblastoma are more likely to have associated symptoms such as fatigue, fever, pain, or weight loss. Plain abdominal radiography and abdominal ultrasonography are good initial diagnostic steps for a child with an abdominal mass. More complex tests, such as computed tomography (CT) or magnetic resonance imaging (MRI), should be performed at a tertiary center with sufficient experience in diagnostic imaging of pediatric tumors.

TABLE. Tumor Location and Differential Diagnosis of Common Malignant Solid Tumors in Pediatric Patients

TUMOR	NEWBORN (<1 Y)	INFANT (1–3 Y)	CHILD (3–11 Y)	ADOLESCENT/YOUNG ADULT (12–21 Y)
Abdominal	Neuroblastoma Mesoblastic nephroma Hepatoblastoma Wilms tumor	Neuroblastoma Wilms tumor Hepatoblastoma Rhabdomyosarcoma	Neuroblastoma Wilms tumor Rhabdomyosarcoma	Germ cell tumor Soft tissue sarcoma Hepatocellular carcinoma
Extremity	Fibrosarcoma	Fibrosarcoma Rhabdomyosarcoma Ewing sarcoma	Rhabdomyosarcoma Ewing sarcoma	Osteosarcoma Ewing sarcoma Soft tissue sarcoma
Genitourinary	Teratoma	Rhabdomyosarcoma Yolk sac tumor Clear cell sarcoma of the kidney	Rhabdomyosarcoma	Germ cell tumor Teratoma
Head and neck	Retinoblastoma Neuroblastoma Rhabdomyosarcoma	Retinoblastoma Neuroblastoma Rhabdomyosarcoma	Rhabdomyosarcoma	Soft tissue sarcoma Nasopharyngeal carcinoma
Thoracic	Neuroblastoma Teratoma	Neuroblastoma Rhabdomyosarcoma Teratoma	Neuroblastoma	Ewing sarcoma

### Thoracic Masses

Similar to abdominal masses, all masses that arise in the thorax require further diagnostic evaluation. Patients with mediastinal masses often present with signs of compression of surrounding structures, including the airway or vasculature, but the mass may present as an incidental finding on a chest radiograph obtained for unrelated reasons. Compression of the airway frequently causes respiratory symptoms such as dyspnea, wheezing, or persistent nonproductive cough not relieved by  $\beta$ -agonist treatment. Vascular compression can result in superior vena cava syndrome, which manifests as facial edema. Masses in the anterior, middle, or posterior mediastinum all may represent malignancy. Anterior mediastinal masses that cause respiratory and vascular compromise frequently are teratomas and most commonly are diagnosed in older adolescents. Masses found in the middle mediastinum are likely to be lymphoma; however, sometimes abdominal solid tumors such as neuroblastoma and rhabdomyosarcoma can metastasize to middle mediastinal lymph nodes. Posterior mediastinal masses generally are neurogenic tumors such as neuroblastoma and ganglioneuroblastoma. Patients with these posterior mediastinal masses may present with signs and symptoms of spinal cord compression, including back pain, paresthesia, weakness, or paralysis. Persistent back pain is unusual in children and should trigger a detailed history and physical examination. Respiratory, vascular, and spinal cord compressions are oncologic emergencies. Patients should be sent to the emergency department for immediate evaluation. Special precautions should be taken into consideration when performing diagnostic imaging studies or other procedures under sedation if airway compression is suspected because supine positioning and muscle relaxation from sedation can exacerbate an already narrowed airway, leading to rapid and sometimes irreversible respiratory failure.

### Fever

Although malignancy is part of the differential diagnosis of fever of unknown origin, it is unlikely to be the sole presenting symptom of a patient with a solid tumor. Solid tumors that manifest with systemic symptoms such as fever include neuroblastoma and Ewing sarcoma. Neuroblastoma will often have accompanying symptoms such as a palpable abdominal mass, generalized malaise, or other unusual but specific symptoms, such as hypertension, Horner syndrome, or opsoclonus-myoclonus-ataxia. Ewing sarcoma often is accompanied by a palpable mass, pain, or limping.

### Bone Pain

Pain is a common presenting symptom for patients diagnosed as having childhood cancer. Bone pain that is localized and progresses in severity should serve as a warning sign for the pediatrician and not be dismissed. In addition, limping or refusal to bear weight is another common sign for children diagnosed as having cancer. Diffuse bone pain can be a manifestation of metastatic solid tumors or hematologic malignancies such as leukemia. Bone pain that is accompanied by systemic symptoms such as night sweats, weight loss, or fever should raise the suspicion of an underlying malignancy. Plain radiographs of the affected area should be obtained in patients with bone pain when cancer is suspected. The presence on plain films of an osteolytic or osteoblastic lesion with or without classic radiologic signs of malignancy, such as Codman triangle, sunburst pattern, or onion skin appearance, requires prompt referral to a pediatric oncologist or an orthopedic oncologist. The most common primary bone tumors are osteosarcoma and Ewing sarcoma, which are seen mainly in adolescents and young adults.

### COMMON PEDIATRIC SOLID TUMORS IN YOUNG CHILDREN

Most pediatric solid tumors are thought to arise from aberrant tissue formation during the normal process of organ development in early infancy or rapid growth in puberty. This article focuses on the clinical manifestations of retinoblastoma, neuroblastoma, hepatoblastoma, and Wilms tumor, the most common pediatric solid tumors in infancy and early childhood.

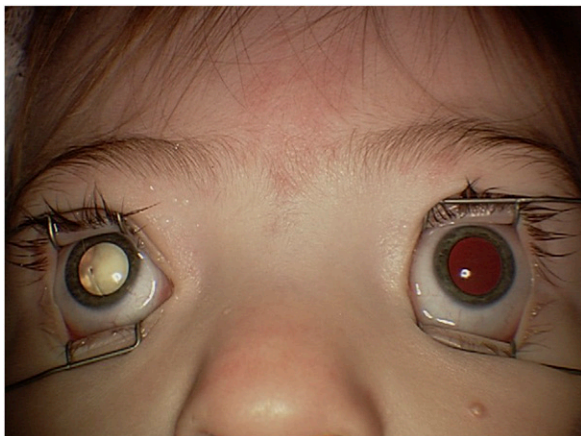
### Retinoblastoma

Retinoblastoma is a malignant tumor that arises from the developing retina in very young children. There are approximately 280 new cases of retinoblastoma diagnosed each year in the United States. The incidence of retinoblastoma is not equally distributed around the world. It seems to be higher in Southeast Asia and South America. The reason for this difference is unknown, although it is thought to be related to genetic and socioeconomic factors. The incidence of retinoblastoma is similar in boys and girls. Approximately 75% of patients with retinoblastoma are diagnosed before reaching age 2 years. Patients with bilateral disease present at an even younger age, usually around 12 months of age. Retinoblastoma can occur as a heritable (25% of cases) or nonheritable (75%) disease. Germ-line mutation in the *RB1* gene, found on the long arm of chromosome 13,

characterizes patients with heritable retinoblastoma. These patients usually present with bilateral disease and develop retinoblastoma at a younger age. Individuals who carry the *RB1* mutation also have increased risk of developing other cancers, such as osteosarcoma, soft tissue sarcomas, or melanoma. Therefore, primary care providers should ensure that families and patients diagnosed as having retinoblastoma seek genetic counseling and molecular testing. The information obtained from additional genetic testing can help estimate the risk of developing other cancers or the need for close surveillance in patients and their siblings.

**Presentation and Diagnosis.** The role of primary care providers is essential in the prompt recognition of leukocoria, white pupillary reflex (Fig 2) instead of the normal red reflex, or strabismus as common manifestations of this malignancy. The American Academy of Pediatrics policy statement recommends evaluation of red reflex periodically as part of regular health supervision visits for the first 5 years after birth. Any asymmetry in the color of the retina or the presence of white spots on physical examination, as well as information provided by the parents regarding asymmetric pupils noted in photographs of the child, should prompt a dilated eye examination under sedation by an ophthalmologist. The early diagnosis of retinoblastoma may be a key factor to prevent extraocular spread, salvage the ocular globe, and preserve vision.

The diagnosis of intraocular disease, retinoblastoma localized to the eye, usually does not require tumor histologic confirmation; therefore, tumor biopsy should not be attempted. Diagnosis and medical treatment are based on direct visualization of retinoblastoma on comprehensive ophthalmologic examination under anesthesia. If enucleation (removal



**Figure 2.** Photograph of leukocoria on the right eye of a patient with retinoblastoma. Red reflex is present on the left eye. (Photo courtesy of Dan S. Gombos, MD, FACS.)

of the ocular globe) is required, evaluation of the enucleated eye should be made by an experienced pathologist to determine the presence of high-risk features, such as choroid involvement or tumor beyond the lamina cribosa, which would require adjuvant therapies. These high-risk features increase the likelihood of extraocular retinoblastoma, with disease extending to the orbit, central nervous system, and, rarely, bone marrow or lymph nodes. Most patients require an MRI of the brain and orbits for complete tumor-staging evaluation. Bone marrow aspirates, bone scintigraphy, and lumbar puncture are usually not indicated unless there is suspicion for systemic spread.

**Risk Grouping and Treatment.** The treatment of retinoblastoma requires a multidisciplinary team approach in specialized centers. Treatment options are dictated by the extent of intraocular, extraocular, and distant metastatic disease and have 3 main goals: to save the patient's life, to preserve vision, and to avoid late-treatment sequelae. Although enucleation generally provides definitive management of the affected eye, in many cases, both vision and the eye can be salvaged using locally directed therapies with or without systemic chemotherapy. In more advanced ocular disease, enucleation may be indicated. In the most advanced cases, high-dose chemotherapy with autologous stem cell transplant (ASCT) and radiotherapy may be necessary. When detected in the early stages, retinoblastoma is a highly curable disease, with more than 90% of patients with localized intraocular disease achieving a long-term cure. However, patients with extraocular or metastatic disease have overall survival of only 50% to 80%, highlighting the importance of early detection. Children with central nervous system involvement particularly have a very poor prognosis. Unfortunately, patients with retinoblastoma in resource-limited countries often reach medical attention with advanced disease, and outcomes in these countries remain lower than those in high-income countries.

Although the outcomes for retinoblastoma are excellent, survivors of retinoblastoma are at high risk for developing second malignant neoplasms. Patients previously treated with radiotherapy are at high risk for sarcomas inside and outside of the radiation field. In addition, those with heritable retinoblastoma have a markedly increased risk of developing a second neoplasm, including some epithelial cancers, sarcomas, and melanoma, independently of radiotherapy.

### Neuroblastoma

Neuroblastoma, the most common extracranial tumor in children, accounts for 8% of all pediatric cancers. An

estimated 700 new cases are diagnosed each year in the United States. The incidence of neuroblastoma is slightly higher in boys than in girls, and the disease affects more white children than those of other races/ethnicities in the United States. The incidence of neuroblastoma is fairly uniform in industrialized nations and seems to be lower in Sub-Saharan Africa for reasons that are unknown. The median age at diagnosis is 19 months, with most patients diagnosed between 0 and 5 years of age. Most cases of neuroblastoma occur in children with no family history or an associated condition. Less than 2% of cases occur in patients with a positive family history, and these patients tend to be diagnosed earlier and may have more than 1 primary tumor. Mutations in the *ALK* gene are found in 75% to 80% of cases of familial neuroblastoma and in 10% of sporadic cases. Mutations in the *PHOX2B* gene are also responsible for approximately 5% of hereditary neuroblastomas and are associated with other neural crest disorders, including Hirschsprung disease and central hypoventilation.

**Presentation and Diagnosis.** Neuroblastoma has a varied clinical presentation. Tumors may arise from the adrenal glands or anywhere along the sympathetic chain. Presentation of disease varies from asymptomatic tumors detected incidentally to systemic life-threatening illness, depending on the extent and location of the disease. Approximately half of all patients have localized or locoregional disease at diagnosis. Abdominal masses account for 75% of primary tumors and present with fullness, constipation, abdominal pain, distention, or hypertension from compression of renal vessels. Thoracic and cervical tumors may be asymptomatic, cause respiratory symptoms from airway compression, or present with Horner syndrome or, rarely, superior vena cava syndrome. Paraspinal tumors may extend into the spinal column and lead to spinal cord compression with resultant weakness, loss of deep tendon reflexes, bowel and bladder dysfunction, and paralysis sometimes resulting in paraplegia. Approximately half of all patients will present with metastatic disease at diagnosis, and these patients may have systemic symptoms, including fever, weight loss, cachexia, and bone pain leading to limping and irritability. The most common sites for metastatic disease include bones, bone marrow, and liver. Neuroblastoma also frequently spreads to the skull and orbital bones, leading to a classic presentation characterized by periorbital ecchymosis, referred to as “racoon eyes.”

Two paraneoplastic syndromes are associated with neuroblastoma. Opsoclonus myoclonus syndrome (OMS) is seen in 2% to 3% of patients with neuroblastoma and manifests with myoclonus, ataxia, and opsoclonus, a rapid

chaotic eye movement. Although most patients with this syndrome have low-stage and low-risk neuroblastoma, their neurologic outcomes are, unfortunately, not as favorable. As many as 80% of these children will have long-term cognitive and motor delays, language deficits, and behavioral problems. Resection of the neuroblastoma may improve symptoms temporarily, but many patients experience recurrence or persistence of OMS. The second paraneoplastic syndrome, vasoactive intestinal peptide (VIP) syndrome, is caused by neuroblastoma tumors secreting VIP. This syndrome presents as abdominal distention, intractable watery diarrhea, hypokalemia, and dehydration. Unlike OMS, resecting the tumor generally cures this condition because VIP is secreted directly by the tumor. Young infants with neuroblastoma may have a distinctive disease presentation with massive hepatomegaly as a result of tumor infiltration of the liver that may result in respiratory compromise from an enlarged abdomen. In addition, young infants may present with skin involvement, characterized by bluish subcutaneous nodules. The role of primary care providers is to recognize the myriad of symptoms with which patients with neuroblastoma may present and to initiate their evaluation and prompt referral.

Most commonly, neuroblastoma is diagnosed on tumor histopathologic analysis of a biopsy specimen. The diagnosis may also be made by finding an elevation in urine or serum catecholamine levels and detecting tumor cells in bone marrow. Staging evaluation includes tumor imaging with CT or MRI. Generally, cross-sectional imaging of the chest, abdomen, and pelvis are performed in the initial evaluation. Distant metastatic disease is evaluated using <sup>123</sup>I-meta-iodo-benzylguanidine (<sup>123</sup>I-MIBG) scintigraphy; <sup>123</sup>I-MIBG is a radiolabeled chemical analogue of norepinephrine that is selectively concentrated in sympathetic nervous tissues, such as neuroblastoma, and is sensitive and specific for neuroblastoma. If the primary tumor is not seen with <sup>123</sup>I-MIBG scintigraphy, positron emission tomography or bone scanning can be used to detect metastatic disease. To evaluate for bone marrow metastasis, bone marrow aspirate and biopsy from at least 2 sites (generally bilateral iliac crests) are performed. Brain imaging is required when clinically indicated based on symptoms or to evaluate the extent of cranial lesions on <sup>123</sup>I-MIBG scintigraphy.

**Risk Grouping and Treatment.** Patients with neuroblastoma are divided into 3 risk groups—low, intermediate, and high—based on risk of disease recurrence. The risk groups are defined based on a variety of clinical and biological factors, and treatment has been tailored to address the specific prognosis of each group. Patients with higher-stage



tumors, particularly metastatic tumors, and patients older than 18 months at diagnosis have worse outcomes. Many biological risk factors, including tumor histologic appearance, DNA ploidy, certain chromosomal deletions or gains, and, importantly, amplification of the oncogene *MYCN*, are included in risk stratification.

Patients with low- and intermediate-risk neuroblastoma represent a heterogeneous group with excellent outcomes. Low-stage tumors with favorable biological markers often do not metastasize, and, therefore, surgical resection may be curative. Chemotherapy is reserved for patients with life- or organ-threatening symptoms, such as spinal cord compression or respiratory compromise. Treatment for intermediate-risk neuroblastoma comprises moderate doses of multi-agent chemotherapy and surgical resection. Neuroblastoma in infants (<1 year of age) tends to regress without treatment. In addition, children younger than 18 months with metastatic neuroblastoma limited to the skin, liver, and bone marrow also may demonstrate spontaneous regression, allowing for observation. However, a subset of infants does require immediate treatment owing to their high risk for complications and death from massive hepatomegaly, liver dysfunction, and respiratory distress.

High-risk neuroblastoma is an aggressive disease with an overall poor outcome. Long-term survival remains less than 50% in large cooperative group studies regardless of more intense and prolonged therapy. High-risk neuroblastoma therapy comprises 3 phases: induction chemotherapy, consolidation, and maintenance therapy. Induction chemotherapy includes high-intensity, multidrug chemotherapy and local-control surgical resection with the goal of maximally reducing tumor bulk at primary and metastatic sites. The consolidation phase of therapy is aimed at eliminating the remainder of disease that has survived induction chemotherapy. In most centers, this goal is achieved by administering high doses of chemotherapy supported by ASCT. Generally, external beam radiotherapy targeted at the primary tumor bed and the remaining MIBG avid sites of metastatic disease follows ASCT. Finally, treatment concludes with maintenance chemotherapy to target any remaining minimal residual disease. Maintenance therapy comprises retinoids, which induce cell differentiation, and immunotherapy targeting neuroblastoma-specific surface markers. These agents work via different mechanisms than those of conventional chemotherapy and are thought to eradicate residual clones that have acquired chemotherapy resistance. A recently completed clinical trial demonstrated the efficacy of a human-mouse monoclonal antibody Ch14.18 in improving 2-year, event-free, and overall survival. This drug, dinutuximab, gained Food and Drug

Administration (FDA) approval in 2015 and is the first drug approved specifically for the treatment of high-risk neuroblastoma.

### Hepatoblastoma

Hepatoblastoma is the most common malignant liver tumor in children. An estimated 150 new cases are diagnosed each year in the United States. The incidence of hepatoblastoma is slightly higher in boys than in girls, and the disease affects more white children than those of other races/ethnicities in the United States. The mean age at diagnosis is 19 months. Although most cases of hepatoblastoma are sporadic, some are associated with genetic abnormalities, including Beckwith-Wiedemann syndrome, familial adenomatous polyposis, and trisomy 18. Hepatoblastoma has also been associated with numerous gestational factors. Children born at very low birthweight (<1,500 g) have a 20-fold increased risk of developing hepatoblastoma compared with normal-birthweight peers. Pre-eclampsia, polyhydramnios, oligohydramnios, high maternal prepregnancy weight, and infertility treatment have also been associated with an increased incidence of hepatoblastoma. Epidemiologic studies suggest that the incidence in the United States is on the rise, perhaps due to increased survival of very-low-birthweight infants.

**Presentation and Diagnosis.** Hepatoblastoma commonly presents with abdominal distention or palpable abdominal mass, sometimes in association with pain, fatigue, loss of appetite, and vomiting. For liver tumors, the gold standard imaging is either triphasic contrast-enhanced abdominal CT or MRI with hepatocyte-specific contrast agents such as gadoxetate disodium or gabobenate dimeglumine. The MRI provides the best assessment of the margins and vascular anatomy of the tumor. Knowledge of the extent of tumor involvement of major vessels is critical in determining resectability and for surgical planning. In addition to abdominal imaging, a chest CT is recommended because the lungs are the most common sites of metastatic disease.

In addition to imaging studies,  $\alpha$ -fetoprotein (AFP) is a useful biomarker in the diagnosis and monitoring of hepatoblastoma. A markedly elevated AFP level suggests a diagnosis of hepatoblastoma, although concentrations of AFP may be elevated in patients with hepatocellular carcinoma, germ cell tumors, and benign liver tumors, including mesenchymal hamartoma and infantile hemangioma. Of note, elevation of AFP levels is normal in healthy infants and declines gradually until 8 months of age, rendering AFP more difficult to interpret in young children. Therefore, serial monitoring of serum AFP concentration in children

younger than 1 year often is required to distinguish normal physiologic levels from abnormal elevated levels related to malignant tumors.

Histopathologic diagnosis is confirmed after obtaining a biopsy of the mass. Tissue samples may be obtained by percutaneous core needle, laparoscopic core needle, or wedge biopsy. Fine-needle aspiration is not recommended. Histologically, hepatoblastomas are generally heterogeneous tumors with combinations of epithelial, mesenchymal, and undifferentiated elements. Importantly, hepatoblastomas with pure fetal histology and low mitotic activity (up to 2 mitoses per 10 high-power fields)—approximately 7% of hepatoblastomas—have an excellent prognosis. These tumors require no further therapy if they are completely resected. Alternatively, those with predominantly small-cell, undifferentiated histology—approximately 5% of patients—carry the poorest prognosis of all histologic subtypes.

**Risk Grouping and Treatment.** The currently accepted staging system for hepatoblastoma describes tumor extension before any surgical treatment based on the number of involved Couinaud liver segments, vascular extension, and the presence of metastatic and extrahepatic disease. This staging system is referred to as the PRETEXT stage (prior to chemotherapy administration) and the POSTTEXT stage (posterior to neoadjuvant chemotherapy treatment). Risk stratification involves use of PRETEXT, POSTTEXT, tumor histology, presence of metastatic disease, and AFP levels. However, risk group classification and treatment strategies vary among different cooperative study groups.

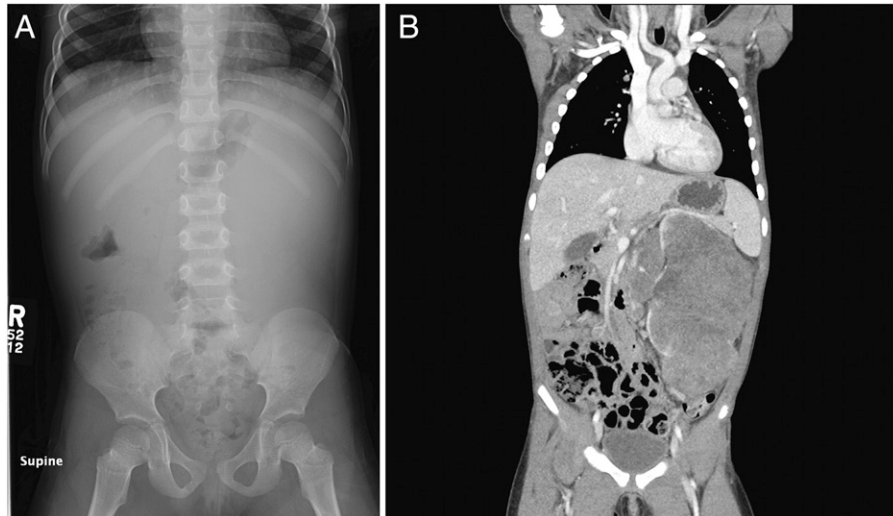
Complete surgical resection is required to achieve a definitive cure for hepatoblastoma. Hence, early consultation with an experienced pediatric liver surgeon is critically important. Patients who undergo a complete resection at the time of diagnosis have an excellent prognosis; however, only one-third to one-half of patients will have resectable disease at presentation. For patients with unresectable disease at diagnosis, neoadjuvant chemotherapy is administered with the goal of achieving resectability. If the tumor is not resectable after 4 cycles of chemotherapy or the tumor is located such that surgical resection will never become possible, patients are listed for orthotopic liver transplant. Complete resection, if attempted, is imperative because rescue transplant has inferior outcomes for patients with incompletely resected disease compared with patients transplanted primarily. Patients with unresectable and metastatic hepatoblastoma may be eligible for a liver transplant provided the metastases are cleared either with chemotherapy or surgical resection before transplant. Patients with resectable hepatoblastoma at diagnosis have excellent overall

survival of more than 90%. For patients with unresectable disease at diagnosis but who receive chemotherapy followed by either complete surgical resection or orthotopic liver transplant, the overall survival range is approximately 60% to 80%. The outcomes for patients with metastatic hepatoblastoma have historically been poor, but survival is possible, unlike the case with many other metastatic solid tumors. Survival from pediatric cooperative group trials has ranged from 18% to 48%.

### Wilms Tumor

Renal tumors account for 7% of all childhood malignancies. Most kidney cancers are Wilms tumor in young children. Approximately, 650 new cases of Wilms tumor are diagnosed each year in the United States. The incidence of Wilms tumor is slightly higher in girls than in boys, and the disease seems to occur more frequently in African American children compared with those of other races/ethnicities in the United States. The incidence of Wilms tumor seems to be similarly distributed worldwide. The mean age at diagnosis is 41 to 46 months for unilateral disease and 29 to 32 months for bilateral disease. Wilms tumor has one of the highest associations with congenital malformation syndromes. Approximately 10% of all Wilms tumors occur in settings of such anomalies. The most common congenital anomalies associated with Wilms tumor are Beckwith-Wiedemann syndrome, isolated hemihypertrophy, WAGR syndrome (characterized by the presence of Wilms tumor, aniridia, genitourinary anomalies, and mental retardation), and Denys-Drash syndrome (characterized by the development of nephropathy, Wilms tumor, and gonadal dysgenesis). Children with an increased predisposition to develop Wilms tumor should be followed closely and undergo abdominal ultrasonography every 3 months until 8 years of age. Genetic counseling should also be considered for children with the aforementioned syndromes and for patients with bilateral Wilms tumor, familial Wilms tumor, or Wilms tumor diagnosed when they are younger than 6 months.

**Presentation and Diagnosis.** The most common presenting symptom of Wilms tumor is an asymptomatic abdominal mass found by a parent or pediatrician (Fig 3). Approximately 40% of patients present with concomitant abdominal pain and 25% of patients develop hypertension caused by increased renin secretion. Gross or microscopic hematuria occurs in one-third of patients with Wilms tumor at presentation and it may be observed intermittently. Less commonly, patients may present with signs and symptoms of mass effect on surrounding structures, including constipation, prominent abdominal wall vessels, and congestive



**Figure 3.** Abdominal radiograph (A) and computed tomographic scan (B) of the abdomen in a patient with Wilms tumor. The patient presented with intermittent gross hematuria and left flank “fullness.” Notice the absence of bowel gas in the left flank due to bowel displacement by the tumor.

heart failure (due to vascular compression). Physical examination should be performed gently because Wilms tumor can be fragile and aggressive palpation of the tumor does not aid in the diagnostic evaluation. Laboratory evaluation of a suspected renal malignancy should include a complete blood cell count, renal function tests including urinalysis and electrolytes, liver function tests, and coagulation studies. Approximately 8% of patients with Wilms tumor can acquire von Willebrand factor deficiency. Abdominal ultrasonography can be performed to confirm that the mass arises from the kidney, to evaluate the contralateral kidney, and to identify intravascular tumor thrombus using color Doppler. Advanced imaging studies with enhanced contrast CT of the abdomen are indicated for evaluation of all renal tumors. A noncontrast chest CT for evaluation of pulmonary metastatic disease can be obtained simultaneously. The histopathologic diagnosis is established after radical nephrectomy either up front or after the administration of chemotherapy. Biopsy (preoperative or intraoperative) generally is not recommended because any biopsy would spread tumor cells in the peritoneum and would upstage tumor extension.

**Risk Grouping and Treatment.** The prognosis of patients with Wilms tumor depends on several factors such as tumor histopathology, extension of disease at diagnosis, molecular features, and the patient’s age. There are 2 main staging and treatment schemas for patients with Wilms tumor. The Children’s Oncology Group staging system relies on up-front radical nephrectomy with sampling of regional lymph nodes and accounts for pathologic and imaging findings; the International Society of Paediatric Oncology staging system

relies on preoperative chemotherapy and local operative findings following chemotherapy. The histopathologic classification divides Wilms tumor into favorable and anaplastic histology, with favorable histology having superior outcomes compared with anaplastic histology. In addition, loss of heterozygosity on chromosomes 1p and 16q, and 1q gain are associated with inferior outcomes. The presence of 1q gain in patients with Wilms tumor with favorable histologic findings has become a powerful predictor of adverse outcome in recent clinical trials. Nonetheless, stage continues to be the stronger predictor of prognosis, with the most favorable outcomes being for patients with low-stage tumors and the least favorable outcomes for patients with metastatic or bilateral disease.

The treatment of Wilms tumor includes surgery, chemotherapy, and sometimes radiotherapy. Therefore, patients with Wilms tumor should be evaluated and treated by a multidisciplinary team of experienced cancer specialists. As mentioned previously, up-front surgical resection with sampling of regional lymph nodes is the surgical management of choice in North America. Care should be taken to avoid tumor rupture or spill during surgery. Multidrug chemotherapeutic regimens vary by stage of disease and across cooperative groups. Flank irradiation generally is reserved for patients with advanced stages and patients with anaplastic Wilms tumor. Whole-abdomen irradiation is used for patients with residual tumor or evidence of peritoneal contamination from tumor rupture or spill. Whole-lung irradiation is used for patients with anaplastic metastatic lung disease and selected patients with unresponsive metastatic disease with favorable histologic findings.



Generally, the outcome for Wilms tumor with favorable histologic findings is considered excellent. Overall survival for these patients ranges from 86% to 98% depending on the stage. The overall survival for anaplastic Wilms tumor is highly dependent on stage and ranges from 33% to 78%, with the lowest survival being for patients with distant metastatic disease. Survivors of Wilms tumor who have 1 kidney should avoid participating in contact sports with significant risks of heavy collision, such as boxing, martial arts, or football.

## ACKNOWLEDGMENT

The authors thank Dr Lee Ligon of the Center for Research, Innovation, and Scholarship, Department of Pediatrics, Baylor College of Medicine, for editorial assistance.

## Summary


- Based on strong research evidence, solid tumors in young children compose a heterogeneous group of malignancies that present with a myriad of clinical manifestations.
- Based on some research evidence as well as consensus, cancer-related symptoms overlap with frequently occurring childhood illnesses. Common complaints in pediatric patients, such as constipation, fever, back pain, bone pain, or limping, are frequently the first signs of malignancy. The role of general pediatricians is to further investigate these symptoms when they do not resolve in a timely manner.
- Based primarily on consensus, when cancer is suspected, general pediatricians should obtain a comprehensive history, perform a detailed physical examination (including blood pressure measurement), and consider obtaining a plain radiograph of the affected body part (chest, abdomen, or limb). Patients with an abdominal mass may be initially evaluated with abdominal ultrasonography.

- Based on some research evidence as well as consensus, prompt referral to a specialized cancer center of children with suspected cancer for evaluation can prevent permanent disease sequelae and may lead to improved outcomes.
- Based on strong research evidence, pediatric solid tumors are managed by surgery, chemotherapy, and radiotherapy depending on the tumor type and stage and the patient age. Children with cancer should be offered to participate in clinical trials if it is possible. The tremendous improvement in the clinical outcome of many pediatric cancers over time has been partially achieved through patient enrollment in clinical trials. Close disease surveillance or additional genetic tests may be indicated based on the presence of congenital malformations or the tumor type.

To view teaching slides that accompany this article, visit <http://pedsinreview.aappublications.org/content/39/2/57.supplemental>.

### Pediatric Solid Tumors of Infancy: An Overview

Wendy Allen-Rhoades, MD  
Sarah B. Whittle, MD, MS  
Nino Rainusso, MD



*Suggested Readings for this article are at <http://pedsinreview.aappublications.org/content/39/2/57>.*

## PIR Quiz

There are two ways to access the journal CME quizzes:

1. Individual CME quizzes are available via a handy blue CME link under the article title in the Table of Contents of any issue.
2. To access all CME articles, click "Journal CME" from Gateway's orange main menu or go directly to: <http://www.aapplications.org/content/journal-cme>.
3. To learn how to claim MOC points, go to: <http://www.aapplications.org/content/moc-credit>.

1. A 3-year-old boy is brought to the physician because the mother had noted a swelling in the abdomen last night when she was bathing him. He has been otherwise well with no bruising, weight loss, fever, or bone pain. His blood pressure is 135/88 mm Hg. Physical examination shows a well-nourished child with a palpable 8-cm mass in the right flank. A urine analysis shows 50 to 100 red blood cells. Which of the following is the most likely diagnosis in this patient?
  - A. Germ cell tumor.
  - B. Leukemia.
  - C. Neuroblastoma.
  - D. Rhabdomyosarcoma.
  - E. Wilms tumor.
2. A 3-year-old boy is brought to the physician with a 3-week history of extremity pain and bruising. The mother noted that he had a swollen abdomen when she was bathing him last night. She states that he has lost weight and has had a low-grade fever. Vital signs show a temperature of 101.3°F (38.5°C), a heart rate of 115 beat/min, a respiratory rate of 18 breaths/min, and blood pressure of 108/65 mm Hg. On physical examination he is thin and in moderate distress, and bruising is noted around the eyes. The abdomen is distended, and a 10-cm right-sided mass is palpated. Which of the following is the most likely diagnosis in this patient?
  - A. Germ cell tumor.
  - B. Leukemia.
  - C. Neuroblastoma.
  - D. Rhabdomyosarcoma.
  - E. Wilms tumor.
3. A 25-year-old woman with a history of bilateral retinoblastoma, for whom you have provided primary care since birth, comes to your office for counseling before decisions about having children. She has been tested and was shown to carry a germ-line mutation of the *RB1* gene. Assuming that her healthy newborn shows the presence of the germ-line mutation of the *RB1* gene on genetic testing, which of the following is the most appropriate follow-up recommendation for this family?
  - A. Close surveillance by an ophthalmologist every 3 months.
  - B. Dilated sedated eye examination if suspected of having a vision defect after 2 years of age.
  - C. No special follow-up is indicated.
  - D. Prophylactic enucleation of both eyes at the time of delivery.
  - E. Routine magnetic resonance imaging (MRI) of the brain and orbits every 3 months.
4. A 5-year-old boy is brought to the physician with a 2-week history of lower back pain, poor appetite, and bruising. Over the past 3 days he has noted weakness in his legs. His mother states that he has had "potty accidents" and is incontinent. On physical examination he has normal respirations and his upper extremities have normal strength. His legs are very weak. He has no reflexes, and rectal tone is decreased. He cannot support himself to stand, and he must be carried. He has decreased sensation to touch below the umbilicus. In addition to urine and serum catecholamines, which of the following is the best next step in management for this patient?
  - A. Bone scan.
  - B. Electromyography.
  - C. Electroencephalography.
  - D. MRI of the spine.
  - E. Physical therapy.

**REQUIREMENTS:** Learners can take *Pediatrics in Review* quizzes and claim credit online only at: <http://pedsinreview.org>.

To successfully complete 2018 *Pediatrics in Review* articles for *AMA PRA Category 1 Credit™*, learners must demonstrate a minimum performance level of 60% or higher on this assessment. If you score less than 60% on the assessment, you will be given additional opportunities to answer questions until an overall 60% or greater score is achieved.

This journal-based CME activity is available through Dec. 31, 2020, however, credit will be recorded in the year in which the learner completes the quiz.



2018 *Pediatrics in Review* now is approved for a total of 30 Maintenance of Certification (MOC) Part 2 credits by the American Board of Pediatrics through the AAP MOC Portfolio Program. Complete the first 10 issues or a total of 30 quizzes of journal CME credits, achieve a 60% passing score on each, and start claiming MOC credits as early as October 2018. To learn how to claim MOC points, go to: <http://www.aapplications.org/content/moc-credit>.

5. A 2-year-old former 26-weeks premature infant is brought to the office because the mother has noted abdominal swelling and decreased appetite. Examination shows a 10-cm mass in the right upper quadrant of the abdomen. An abdominal ultrasonographic image is obtained and shows a large mass infiltrating the liver. The kidneys and suprarenal areas are normal. Laboratory studies and MRI are ordered, and results are pending. The serum level of which of the following is most likely to be significantly elevated in this patient?
- A.  $\alpha$ -Fetoprotein.
  - B. Bilirubin.
  - C. Ceruloplasmin.
  - D. Cholesterol.
  - E. C-reactive protein.

**Pediatric Solid Tumors of Infancy: An Overview**  
Wendy Allen-Rhoades, Sarah B. Whittle and Nino Rainusso  
*Pediatrics in Review* 2018;39;57  
DOI: 10.1542/pir.2017-0057

<b>Updated Information &amp; Services</b>	including high resolution figures, can be found at: <a href="http://pedsinreview.aappublications.org/content/39/2/57">http://pedsinreview.aappublications.org/content/39/2/57</a>
<b>Supplementary Material</b>	Supplementary material can be found at: <a href="http://pedsinreview.aappublications.org/content/suppl/2018/02/01/39.2.57.DC2">http://pedsinreview.aappublications.org/content/suppl/2018/02/01/39.2.57.DC2</a>
<b>References</b>	This article cites 6 articles, 1 of which you can access for free at: <a href="http://pedsinreview.aappublications.org/content/39/2/57.full#ref-list-1">http://pedsinreview.aappublications.org/content/39/2/57.full#ref-list-1</a>
<b>Subspecialty Collections</b>	This article, along with others on similar topics, appears in the following collection(s): <b>Medical Education</b> <a href="http://classic.pedsinreview.aappublications.org/cgi/collection/medical_education_sub">http://classic.pedsinreview.aappublications.org/cgi/collection/medical_education_sub</a> <b>Journal CME</b> <a href="http://classic.pedsinreview.aappublications.org/cgi/collection/journal_cme">http://classic.pedsinreview.aappublications.org/cgi/collection/journal_cme</a> <b>Hematology/Oncology</b> <a href="http://classic.pedsinreview.aappublications.org/cgi/collection/hematology:oncology_sub">http://classic.pedsinreview.aappublications.org/cgi/collection/hematology:oncology_sub</a> <b>Cancer/Neoplastic</b> <a href="http://classic.pedsinreview.aappublications.org/cgi/collection/cancer:neoplastic_sub">http://classic.pedsinreview.aappublications.org/cgi/collection/cancer:neoplastic_sub</a>
<b>Permissions &amp; Licensing</b>	Information about reproducing this article in parts (figures, tables) or in its entirety can be found online at: <a href="https://shop.aap.org/licensing-permissions/">https://shop.aap.org/licensing-permissions/</a>
<b>Reprints</b>	Information about ordering reprints can be found online: <a href="http://classic.pedsinreview.aappublications.org/content/reprints">http://classic.pedsinreview.aappublications.org/content/reprints</a>



## **Pediatric Solid Tumors of Infancy: An Overview**

Wendy Allen-Rhoades, Sarah B. Whittle and Nino Rainusso

*Pediatrics in Review* 2018;39;57

DOI: 10.1542/pir.2017-0057

The online version of this article, along with updated information and services, is located on the World Wide Web at:

<http://pedsinreview.aappublications.org/content/39/2/57>

Pediatrics in Review is the official journal of the American Academy of Pediatrics. A monthly publication, it has been published continuously since 1979. Pediatrics in Review is owned, published, and trademarked by the American Academy of Pediatrics, 345 Park Avenue, Itasca, Illinois, 60143. Copyright © 2018 by the American Academy of Pediatrics. All rights reserved. Print ISSN: 0191-9601.

# American Academy of Pediatrics

DEDICATED TO THE HEALTH OF ALL CHILDREN®

