

# Pediatric Solid Tumors in Children and Adolescents: An Overview

Wendy Allen-Rhoades, MD,\* Sarah B. Whittle, MD, MS,\* Nino Rainusso, MD\*

\*Department of Pediatrics, Section of Hematology-Oncology, Baylor College of Medicine, Texas Children's Cancer and Hematology Centers, Houston, TX

## Education Gaps

Pediatricians should recognize the role of age, genetic conditions, and environmental exposures in the development of malignant solid tumors in children and adolescents.

## Objectives After completing this article, readers should be able to:

1. Identify the signs and symptoms of extracranial germ cell tumors, osteosarcoma, Ewing sarcoma, thyroid cancer, and melanoma in pediatric patients.
2. Identify the genetic conditions and environmental exposures associated with different cancer types in adolescents.
3. Recognize general aspects of the multidisciplinary treatment approach in patients with extracranial germ cell tumors, osteosarcoma, Ewing sarcoma, thyroid cancer, and melanoma.

## INTRODUCTION

Although hematologic and central nervous system malignancies continue to be the most common cancers in adolescents, extracranial malignant solid tumors represent, as a group, 52% of cancers in patients in the 15- to 19-year-old age group (Fig 1). The tumor distribution of malignant pediatric solid tumors in adolescents is different compared with that of younger children, in whom embryonal or developmental cancers, such as retinoblastoma, neuroblastoma, or hepatoblastoma, are more prevalent. The most common malignant solid tumors in adolescents are extracranial germ cell tumors (GCTs), bone and soft tissue sarcomas, melanoma, and thyroid cancer. The diagnosis and treatment of adolescents with cancer also have particular challenges related to patient age, such as adherence to therapy, need for psychological support, concerns about body image, and fertility preservation. In this review, we offer a general description of the clinical presentation and treatment of the most common malignant pediatric solid tumors in adolescents.

**AUTHOR DISCLOSURE** Drs Allen-Rhoades and Whittle have disclosed no financial relationships relevant to this article. Dr Rainusso has disclosed that he has received a career development award grant from St. Baldrick's Foundation and a sarcoma scholar grant from Snowdrop Foundation. This commentary does not contain a discussion of an unapproved/investigative use of a commercial product/device.

## ABBREVIATIONS

<sup>131</sup> I	iodine 131
AFP	α-fetoprotein
β-HCG	β-human chorionic gonadotropin
CT	computed tomography
EWS	Ewing sarcoma
GCT	germ cell tumor
MRI	magnetic resonance imaging
OS	osteosarcoma
PTC	papillary thyroid cancer
SNL	sentinel lymph node
XP	xeroderma pigmentosum

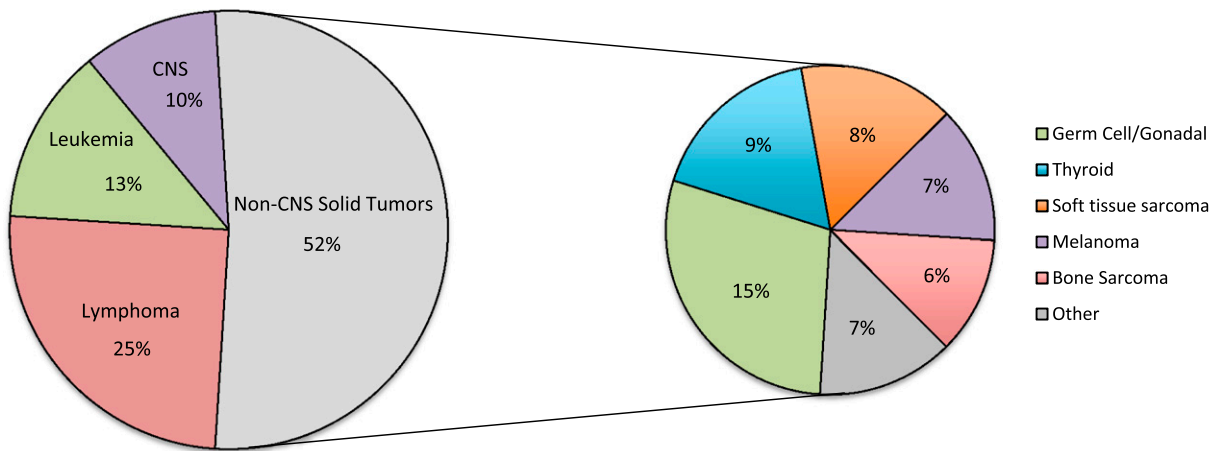


Figure 1. Distribution of pediatric cancers in adolescents aged 15 to 19 years. Extracranial solid tumors are 52% of all malignancies in this age group.

### EXTRACRANIAL GCTs

Germ cell tumors are a rare and heterogeneous group of benign and malignant tumors representing a variety of histologic diagnoses and tumor locations. They arise from primordial germ cells that migrate during embryogenesis along the midline of the body to the gonadal ridges and differentiate into ovarian and testicular tissues. Germ cell tumors can arise in any of the sites along the migration path. Although GCTs also occur in the brain, in this review we focus on those occurring outside of the central nervous system. These tumors occur most frequently in adolescents, representing 14% of cancers between ages 15 and 19 years. Also, GCTs may present in the fetal/neonatal age group, most commonly as benign teratomas of the head and neck, retroperitoneum, or sacrococcygeal region.

Children with disorders of sex development are at increased risk for GCTs. Children with Swyer syndrome (XY gonadal dysgenesis), in which patients are phenotypically female but have a male karyotype and gonadal dysgenesis, are at increased risk for malignant transformation of the nonfunctional gonadal tissue. Klinefelter syndrome (47,XXY) and Turner syndrome (45,Xo) are associated with mediastinal GCTs and gonadoblastoma, respectively. Although gonadectomy is recommended for some individuals with disorders of sex development, this determination should be made based on a multitude of factors, including karyotype, molecular and hormonal data, gonadal morphology, and psychosocial factors, including individual comfort with risk of GCT. In addition, boys with cryptorchidism are at higher risk for testicular GCTs. Orchidopexy before puberty reduces this risk.

Germ cell tumors can be categorized based on location and histologic features. Gonadal GCTs occur in the ovaries or testis, and extragonadal GCTs are found in midline sites,

including the head and neck, mediastinum, retroperitoneum, or sacrococcygeal region. Histologically, they are categorized into teratomas (mature or immature) or malignant GCTs. Teratomas are the most common histologic subtype of GCT, with mature being more common than immature teratomas. Mature teratomas are benign tumors, comprised entirely of well-differentiated tumors from all 3 germ cell layers (ectoderm, mesoderm, and endoderm). Although any tissue type may be found in a mature teratoma, the most common are skin, adipose, intestinal, and cystic structures lined by epithelium. In addition to containing tissues from the 3 germ cell layers, immature teratomas also contain variable amounts of immature tissue, primarily neuroepithelial in origin. Immature teratomas are graded according to the amount of immature neural tissue found, from 0 to 3, and higher grades are more likely to exhibit malignant behavior. Malignant GCTs are a heterogeneous group of tumors classified according to their cell of origin and location. Tumors containing 2 or more histologic subtypes are termed *mixed malignant GCTs* (Table 1).

### Clinical Presentation and Diagnosis

The clinical presentation of GCTs in children is variable, reflecting the heterogeneity of histology and tumor locations. Metastatic disease occurs in 20% of patients and is most commonly found in the lungs, but it may also involve bone, liver, and brain. Testicular GCTs present as a painless swelling of 1 testis and ovarian GCTs usually present with gradual onset of abdominal distention. Acute onset of pain may suggest ovarian torsion from tumor or intratumoral hemorrhage, requiring prompt evaluation. Identification of any midline tumor should prompt consideration of a GCT. Mediastinal tumors present with symptoms related to compression of structures in the mediastinum, including airway

TABLE 1. **Extracranial Germ Cell Tumors (GCTs)**

TUMOR HISTOLOGY	COMMON TUMOR LOCATIONS
<b>Teratomas</b>	
Mature teratoma	Mediastinum, sacrococcyx, ovary, testis
Immature teratoma	Sacrococcyx, ovary
<b>Malignant GCTs</b>	
Yolk sac tumor	Sacrococcyx, testis, ovary
Germinoma	Mediastinum, testis (seminoma), ovary (dysgerminoma)
Embryonal carcinoma	Testis
Choriocarcinoma	Mediastinum, ovary
Gonadoblastoma	Dysgenetic gonads (phenotypic female subjects)
<b>Mixed GCTs</b>	Extragenital, ovary, testis (tumors contain $\geq 2$ of the malignant histologies listed above)

compression, superior vena cava syndrome, or heart failure. Sacrococcygeal teratomas are the most common GCTs in infants and generally are diagnosed either by prenatal ultrasonography or at the time of birth. These unique tumors are classified according to the degree of externalization versus internalization. Type I to III tumors present with visible or palpable masses in the sacrococcygeal region. Type IV tumors may present with constipation, pain, or symptoms of spinal cord dysfunction. Evaluation of the primary tumor site includes ultrasonography for testicular tumors and cross-sectional imaging with magnetic resonance imaging (MRI) or computed tomography (CT) for all other sites. Chest CT should be performed to evaluate for lung metastasis. Whole-body bone scan and/or MRI of the brain is obtained if the patient has symptoms consistent with involvement of these sites as well as in those with metastatic choriocarcinoma. The definitive diagnosis is made from histologic examination of tumor tissue obtained from biopsy or resection of the mass depending on the location and extent of disease at presentation. Serum tumor markers can be very useful in the diagnosis and monitoring of progression and recurrence of GCTs.  $\alpha$ -Fetoprotein (AFP) is produced in early embryogenesis by the yolk sac. Elevated serum AFP levels in patients with GCTs indicate the presence of malignant components such as yolk sac or embryonal carcinoma. In young infants, serum AFP levels can be difficult to interpret because AFP levels at birth are variable and the half-life varies during the first year of life. Elevations in

AFP levels are also associated with hepatoblastoma and some benign liver conditions.  $\beta$ -Human chorionic gonadotropin ( $\beta$ -HCG) is another serum marker used in the diagnosis and monitoring of GCTs.  $\beta$ -Human chorionic gonadotropin is normally produced by the placenta and its elevation in patients with GCTs indicates the presence of elements related to syncytiotrophoblasts, often found in germinomas, choriocarcinoma, or embryonal carcinoma. Similar to AFP,  $\beta$ -HCG levels may also be elevated in non-GCT malignancies, including neuroendocrine tumors and hepatic tumors, and in nonmalignant conditions resulting in elevation in luteinizing hormone. In addition to AFP and  $\beta$ -HCG, other tumor markers used in the detection and monitoring of GCTs include inhibin, estrogen, and testosterone.

### Tumor Staging and Treatment

Staging of GCTs is complex, varies among different cooperative oncology groups, and is beyond the scope of this review. Tumor site and stage are combined to assign patients to risk treatment groups, which are also variable across cooperative oncology groups, but generally include a low-risk classification managed with surgical resection and surveillance, an intermediate-risk group of patients who have excellent outcomes with chemotherapy-based regimens, and a high-risk group for whom outcomes are poor with current treatment modalities. Treatment for mature teratomas is surgical resection alone. Particularly for sacrococcygeal teratomas, complete resection is important to reduce the risk of recurrence. Although surgical resection is also the mainstay of treatment for immature teratomas, the use of adjuvant chemotherapy is controversial. Gynecologic oncologists traditionally have treated women with ovarian immature teratomas with chemotherapy based on a study reporting high recurrence rates in these patients with surgery alone. However, pediatric trials have not demonstrated similar results, and pediatric oncologists have not generally given chemotherapy to this population.

Malignant GCTs are treated with surgical resection followed by chemotherapy. However, no study has clearly demonstrated superior outcomes for those with up-front surgical resection before chemotherapy; therefore, when the risk of surgical resection is high, chemotherapy may be given in an attempt to shrink the tumor before proceeding with surgery. Surgical approaches vary based on the anatomical location of the tumor. Importantly, surgical resection of testicular tumors should use an inguinal approach rather than a trans-scrotal approach due to potential contamination of lymphatic channels in the scrotum and upstaging of the patient. Ovarian masses suspicious for malignancy should be resected with the ovary and mass intact with the intent to keep the capsule intact. Complete

surgical staging, including peritoneal washings and inspection of the contralateral ovary, retroperitoneal lymph nodes, and omentum, is required to determine disease stage and guide chemotherapy decision making. Adjuvant chemotherapy with platinum-based regimens have dramatically increased the survival of patients with malignant GCTs. Patients with stage 1 testicular and ovarian malignant GCTs are generally not treated with chemotherapy; however, those with stage 2 and higher, as well as all patients with extragonadal GCTs, are treated with a variable number of cycles of chemotherapy regimens containing cisplatin, etoposide and bleomycin.

The outcomes for children with GCTs are excellent overall. Prognosis depends on stage of disease, histologic features, age of the patient, and location of the tumor. For many groups, overall survival approaches 100%, although the prognosis of high-risk patients with metastatic disease remains dismal. Unlike many other solid tumors in children, salvage therapy after tumor relapse is often successful for GCTs. The focus of recent clinical trials has been on reducing exposure to chemotherapy drugs to reduce the incidence of late effects, including hearing loss, renal injury, and pulmonary toxicity. In addition, collaborations between pediatric and adult cooperative groups are under way to standardize the staging, risk stratification, and treatment approaches for patients with GCTs.

## OSTEOSARCOMA

Osteosarcoma (OS) is the most common malignant bone tumor in children and adolescents and accounts for 2.8% of all pediatric cancers. Each year in the United States there are an estimated 450 new cases of OS diagnosed in patients younger than 20 years. The incidence of OS is slightly higher in males and in African American children. The median age at diagnosis is 16 years, with most patients being diagnosed between ages 14 and 19 years. Most cases of OS occur in children with no family history of cancer or associated conditions, but a minority of cases are diagnosed in patients with cancer predisposition syndromes, such as Li-Fraumeni syndrome (mutations in the *TP53* gene), hereditary retinoblastoma (mutations in the *RB* gene), and Rothmund-Thomson syndrome (mutations in the *REQL4* gene). A small number of OS cases also arise in patients who have previously received radiotherapy.

### Clinical Presentation and Diagnosis

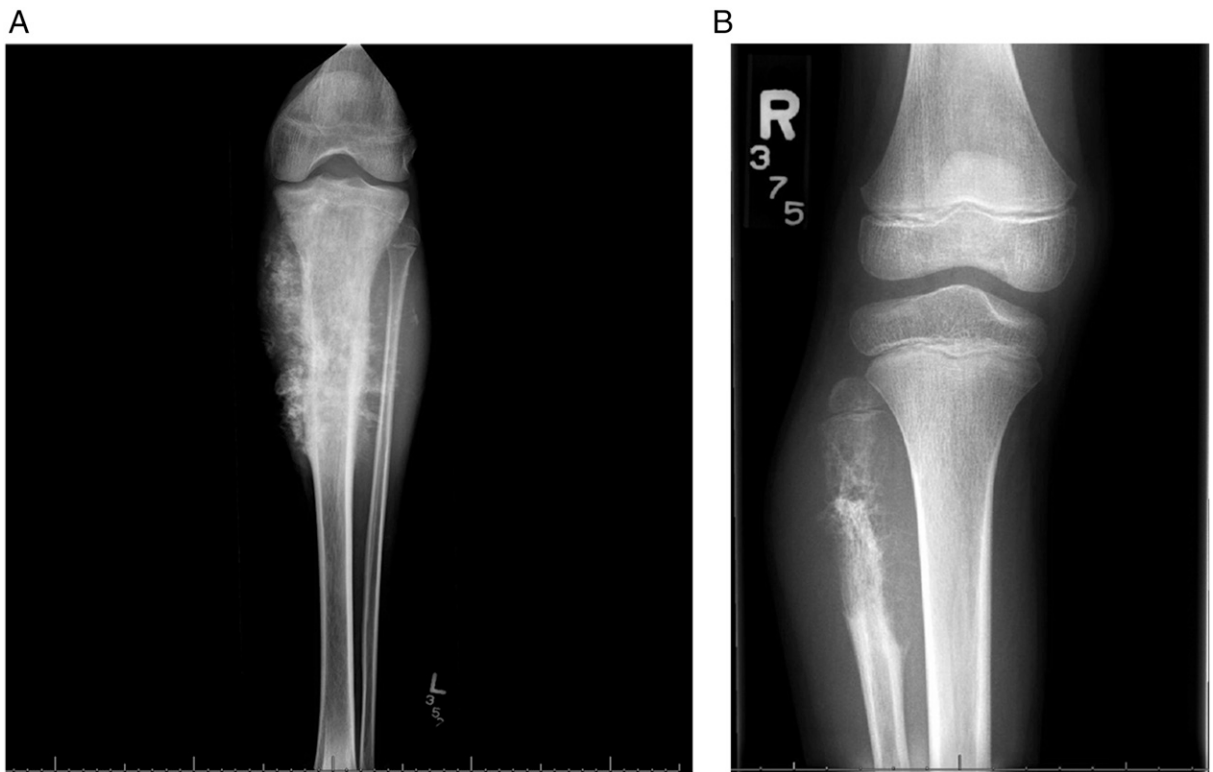The most common presenting symptom is pain with or without a visible enlarging mass. Most cases of OS arise around the knee, in either the metaphysis of the distal femur

or proximal tibia, and the next most common site is in the hip or pelvis. Tumors are usually first identified on plain radiographs, typically demonstrating aggressive periosteal reactions with the classic sunburst pattern and Codman triangle (Fig 2A). Radiographs may also show a pathologic fracture associated with the tumor. A contrast-enhanced MRI of the affected area should be obtained before tumor biopsy for planning purposes. If the lesion is in an extremity, the MRI should extend to the joints above and below the affected bone to evaluate for extent of involvement. A tumor biopsy is required to establish the diagnosis and should be performed at an institution familiar with processing malignant bone tumors. Historically, open biopsy has been the preferred tumor biopsy method for diagnostic purposes. Recent advances in interventional radiology techniques using core needle biopsies combined with fine-needle aspiration (FNA) have proved to also be highly accurate to establish the diagnosis of OS. Once the diagnosis of OS is established, a metastatic evaluation including a noncontrast CT scan of the chest to evaluate for lung metastasis and a technetium-99 whole-body bone scan to evaluate for other bony lesions should be completed.

### Tumor Staging and Treatment

Osteosarcoma is classified as localized (nonmetastatic) or metastatic. The presence of metastasis at diagnosis remains the strongest predictor of clinical outcome. Approximately 20% of patients will be diagnosed as having distant metastatic disease at the time of diagnosis. The most common site of metastasis is the lungs, followed by other bones. The standard treatment approach for patients with OS includes neoadjuvant chemotherapy, followed by surgical resection and then consolidative chemotherapy. Complete surgical resection of the primary tumor is critical in OS and should be performed by an experienced oncologic orthopedic surgeon. Although amputation of an affected limb is always an option for tumors in the extremities, most patients are now able to have a limb-sparing procedure. Limb salvage options include endoprosthesis placement, bone grafting, or rotationplasty. Patients with lung metastases should undergo thoracotomies during consolidation chemotherapy to remove any detectable lesions by manual surgical exploration. Bilateral thoracotomies should be considered even if all lesions have resolved on chest CT because small lesions can persist that are not visible on imaging yet can be palpated by the surgeon for removal.

The outcomes for children and adolescents with OS vary widely depending on metastatic status. Patients with localized disease have 5-year overall survival of approximately 70% to 75%, but patients with metastatic disease have 5-year



**Figure 2.** A. Aggressive periosteal reaction with the sunburst pattern in the proximal tibia of a patient with osteosarcoma. B. Destructive lesion with moth-eaten appearance of the proximal fibula in a patient with Ewing sarcoma.

overall survival of less than 30%. Patients with metastatic disease to the lungs have a slightly better survival rate than patients with multiple bones involved. Patients with both lung and bone metastasis have extremely poor outcomes. In addition, the percentage of tumor necrosis after neoadjuvant chemotherapy is prognostic, and patients with greater than 90% tumor necrosis have better outcomes than those with less tumor necrosis. The focus of recent clinical trials has been to intensify treatment for patients with metastatic disease and poor tumor necrosis, but the results have been disappointing and currently the treatment remains the same for both localized and metastatic disease, except for surgical resection of all sites of metastasis.

### EWING SARCOMA

Ewing sarcoma (EWS), the second most common malignant bone tumor in children and adolescents, accounts for approximately 1.9% of all pediatric cancers. Each year in the United States there are an estimated 300 new cases of EWS diagnosed in patients younger than 20 years of age. The median age at diagnosis is 15 years, and most patients are diagnosed between ages 12 and 18 years. The incidence of EWS is slightly higher in males and in white children.

Approximately 20% of EWS arise in extraosseous locations. Unlike OS, there are no cancer predisposition syndromes associated with EWS.

### Clinical Presentation and Diagnosis

Patients with EWS often present with pain to the affected area with or without a palpable mass. Patients may also present with a limp or refusal to bear weight on the affected limb. Unlike OS, EWS can also present with systemic symptoms such as fever, fatigue, and weight loss. The most common site for EWS is the lower extremities (femur, tibia, and fibula), and lesions are often centered in the diaphysis of the long bones. Approximately 20% of EWS lesions are considered extraosseous, arising in the soft tissues. The trunk is the most common site for these extraosseous EWS tumors.

In primary bone EWS, plain radiographs may have a moth-eaten appearance of the affected bone or an onion skin periosteal reaction (Fig 2B). There is often a substantial soft tissue component of primary bone EWS tumors that may be visible on radiographs. Similar to OS, a contrast-enhanced MRI of the affected area should be obtained before tumor biopsy for planning purposes, and for extremity tumors, the MRI should extend to the joint above and below the affected

bone to evaluate for extent of involvement. The definitive diagnosis of EWS is made through tissue biopsy, either an open biopsy performed by an oncology surgeon or core needle biopsy performed by an interventional radiologist. Nearly all EWS tumors have a pathognomonic chromosomal translocation involving the *EWSR1* gene, which is found on the long arm of chromosome 22. The 2 most common translocation partners are *FLI1* and *ERG*, which account for approximately 95% of translocation partners in EWS, and the resultant fusion proteins are oncogenes. Tumor biopsy samples of suspected EWS cases should be sent for molecular testing of the *EWSR1* translocations with either fluorescence in situ hybridization or reverse transcriptase polymerase chain reaction using specific primer sets. Once the diagnosis of EWS is confirmed, a metastatic evaluation should be completed, including a noncontrast CT of the chest, bilateral bone marrow aspirate and biopsies, and either a technetium-99 whole-body bone scan or a positron emission tomographic (PET) scan.

### Tumor Staging and Treatment

Similar to OS, EWS is classified as metastatic or localized, and the presence of metastasis at diagnosis remains the strongest predictor of outcome. Approximately 25% of patients will be diagnosed as having distant metastatic disease at the time of diagnosis. The most common site of metastasis is the lungs, followed by other bones, bone marrow, and, rarely, lymph nodes. The standard treatment of EWS includes neoadjuvant chemotherapy, followed by local control of the primary tumor and consolidative chemotherapy. If the primary tumor is surgically resectable, surgery is the treatment of choice, with the goal of complete resection. Unlike OS, EWS is radiation sensitive; thus, radiotherapy is an alternate mode of local control for patients with unresectable tumors. All patients with lung metastases should undergo bilateral lung irradiation at the end of therapy even if lesions have resolved on chest CT. There is no role for surgical resection of lung metastases in EWS.

The outcomes for children and adolescents with EWS depend on metastatic status and site of disease. Patients with localized disease have 5-year overall survival of approximately 70% to 75%, but patients with metastatic disease have 5-year overall survival of 15% to 30%. Patients with distal extremity tumors have better outcomes than those with proximal or pelvic tumors, which may be due to the increased likelihood of complete surgical resection for distal extremity lesions. In addition, patients younger than 10 years, including infants, tend to have better outcomes than older patients for unclear reasons. The most recent

cooperative trial in the United States showed improved outcomes for localized patients with increased dose intensity by compressing chemotherapy cycles to every 2 weeks as opposed to every 3 weeks. Current clinical trials are under way to identify novel agents for patients with metastatic disease.

### THYROID CANCER

Thyroid carcinoma is the second most common extracranial solid tumor in adolescents (15–19 years old). There are approximately 1,100 new cases in the United States every year. Females are 5 times more affected than males and adolescents have an almost 10-fold greater incidence of thyroid cancer than young children. There has been an increased incidence of thyroid cancers in adolescents in the past 20 years in the United States for reasons that are unknown. This increased trend cannot be solely attributed to early detection because the number of thyroid cancers was greater for all tumor sizes. Papillary thyroid cancer (PTC) is the most common type of thyroid cancer, representing more than 90% of cases. Follicular, medullary, and anaplastic thyroid cancers are rare in children. The following review focuses on PTC.

The risk of developing PTC is significantly increased in children exposed to ionizing radiation. A decade after the Chernobyl nuclear accident, childhood survivors had a 10-fold increased incidence of PTC. Young children, particularly those younger than 5 years, previously treated with radiotherapy for head, neck, or mediastinal cancers have an increased risk of PTC up to 25 years after radiation exposure. There are several genetic disorders that predispose to thyroid cancer. Patients with *APC*-associated polyposis, *PTEN* hamartoma syndrome, *DICER1* syndrome, Carney complex (mutation on *PRKAR1A* gene), Werner syndrome (mutation on *WRN* gene), or familial nonmedullary thyroid cancer have an increased incidence of thyroid cancer. Patients at increased risk for PTC should have an annual physical examination to assess for palpable thyroid nodules, thyroid gland asymmetry, or cervical lymphadenopathy, and should be referred to specialized centers for appropriate follow-up and genetic counseling.

### Clinical Presentation and Diagnosis

Patients with PTC usually present with a painless thyroid mass and/or enlarged cervical lymph nodes. Thyroid nodules diagnosed in children have a greater risk of malignancy (26%) compared with those in adults (5%–10%). Children with PTC are also more likely to present with regional lymph node involvement (up to 50%), extrathyroidal extension, and



lung metastasis (20%–30%) than adults. Another difference between pediatric and adult PTC is the frequency of different gene tumor mutations; *RET/PTC* gene rearrangement and *BRAF* mutation are the most common mutations observed in pediatric PTC.

The initial evaluation of children with solitary thyroid nodule should include high-quality thyroid ultrasonography and serum thyrotropin, serum thyroglobulin, and thyroglobulin antibody levels. Patients should undergo nuclear thyroid scintigraphy if thyrotropin levels are suppressed to differentiate between a hypofunctioning or hyperfunctioning thyroid nodule. An FNA under ultrasonography guidance of the thyroid nodule should be strongly considered if the patient has risk factors for thyroid cancer, the presence of “malignant” features on ultrasonography (hypoechoogenicity, irregular margins, increased intranodular blood flow, or microcalcifications), a hypofunctioning nodule, or nodule size greater than 1 cm. Surgery (lobectomy plus isthmusectomy) may be considered in patients with hyperfunctioning nodules.

### Tumor Staging and Treatment

Once the diagnosis of PTC is established, patients should have a comprehensive evaluation of the neck by ultrasonography using a high-resolution probe and Doppler technique. A contrast-enhanced CT scan of the chest and neck should be considered for those with evidence of cervical lymph node involvement. There is no role for routine use of whole-body bone scan or PET/CT scan in PTC.

Overall, the clinical outcome of children and adolescents with PTC is excellent, with 10-year survival of nearly 100% even in patients who present with distant metastases. The treatment of PTC includes surgical resection of the thyroid gland, dissection of cervical lymph nodes, and administration of radioactive iodine. For patients with PTC, total thyroidectomy is the recommended treatment of choice, which should ideally be performed by an experienced surgeon. Lateral neck dissection is performed only in patients with histologic confirmation of lymph node involvement and should not be done routinely for prophylactic purposes. The surgical complications of total thyroidectomy include hypoparathyroidism secondary to removal of parathyroid glands and recurrent laryngeal nerve damage.

A whole-body scan is obtained within 12 weeks after total thyroidectomy to identify residual disease and the presence of lung metastasis. The use of radioactive iodine ablation with iodine <sup>131</sup>I (<sup>131</sup>I) is recommended in patients with persistent or unresectable locoregional/nodal disease and distant metastasis. This treatment may be provided more than once and requires special preparation, withdrawing

levothyroxine supplementation for at least 14 days to facilitate <sup>131</sup>I uptake by tumor cells. The late effects of <sup>131</sup>I therapy include salivary gland dysfunction, bone marrow suppression, and increased risk of secondary malignancies.

The American Thyroid Association Task Force on Pediatric Thyroid Cancer published a guideline for the management of thyroid nodules and treatment of PTC in 2015. These guidelines recommended categorizing patients with PTC into 3 risks groups (low, intermediate, and high risk) based on tumor extension at diagnosis to determine the extent of postoperative evaluation, to identify patients who would benefit from <sup>131</sup>I therapy, and to establish the frequency of surveillance evaluations. The American Thyroid Association guidelines also emphasized that children with PTC should be evaluated in specialized centers by a multidisciplinary team.

### MELANOMA

Melanoma is the most common skin cancer in children and adolescents. There are approximately 300 to 500 new cases in the United States every year. Melanoma annual incidence increases with age and accounts for approximately 7% of all cancers in adolescents. Although the incidence of pediatric melanoma increased by 2% per year between 1973 and 2009 in the United States, a recent review suggests a decrease of the incidence of melanoma in children from 2000 to 2010. This decrease in incidence may be related to changes in sun protection practices and imposed limitations to the use of artificial tanning devices in young people.

Some genetic conditions increase the risk of developing melanoma. Xeroderma pigmentosum (XP) is a rare autosomal recessive disorder characterized by extreme sensitivity to UV light, keratosis, and neurologic manifestations. Patients with XP carry a genetic defect that significantly impairs the ability to repair DNA damage after UV light exposure. Approximately 5% to 13% of patients with XP will develop melanoma by age 21 years, and most affected individuals will develop nonmelanoma skin cancers by age 8 years. Protection from sunlight and early detection of malignant skin lesions are essential in these children.

Familial atypical multiple mole and melanoma syndrome is an autosomal dominant condition associated with mutations in the *CDKN2A* gene. These patients have a family history of melanoma and carry an increased risk of melanoma and pancreatic cancer. These individuals often develop more than 50 atypical nevi throughout their lives and require close clinical follow-up, protection from sun exposure, and genetic counseling. Patients with congenital melanocytic nevi also have an increased risk of developing

melanoma during their lifetime. These melanocytic lesions are multiple, may be small or very large (>20 cm), and may have multiple satellite nevi. Approximately 2.5% of patients with large lesions develop melanoma. For half of these children, melanoma develops in the first 5 years of life. The recommended treatment is prophylactic excision of big lesions if feasible.

Immunosuppression, both congenital and acquired, is a well-established risk factor for melanoma. Individuals with immunodeficiency conditions, such as chronic granulomatous disease or human immunodeficiency virus, and organ transplant recipients have a 3- to 6-fold increased risk of developing melanoma; therefore, children with immunosuppression should have a complete skin examination as part of their regular clinical evaluation.

The most common risk factor associated with both melanoma and nonmelanoma skin cancers is sun exposure. The American Academy of Pediatrics recommends wearing proper clothing and hats, applying sunscreen, wearing sunglasses, and avoiding sun exposure between 10 AM and 4 PM, when the sun's rays are strongest. The use of artificial tanning devices is discouraged, and access to tanning salons is prohibited in children younger than 18 years in many parts of the United States.

### Clinical Presentation and Diagnosis

The diagnosis of melanoma in children can be challenging because skin lesions usually do not have the ABCDE features (Asymmetry, irregular Borders, uneven Color distribution, Diameter >6 mm, Evolving nevus) observed in adult patients with melanoma. Salient characteristics in pediatric melanoma are the presence of amelanocytic lesions and their evolution over time. Modified ABCDE criteria have been proposed for children with suspicious lesions (Table 2). Clinical evaluation of pediatric melanoma involves a comprehensive skin examination including mucosal surfaces, interdigital spaces, and palpation of lymph nodes adjacent to any suspicious skin lesions. The diagnosis of melanoma is established after performing an excisional biopsy. The entire lesion should be removed, including the subcutaneous fat, with 3-mm margins if possible. An experienced dermatopathologist should evaluate the biopsy due to the existence of distinct melanocytic lesions with atypical features that share some histologic characteristics with benign nevi and melanoma. These lesions, named Spitz tumors or nevi, may be benign but can be indistinguishable pathologically from melanoma. Therefore, Spitz tumors should be completely excised with clear margins and initially managed as melanoma. Comprehensive genomic studies such as fluorescence in situ hybridization or

TABLE 2. **Modified ABCDE Criteria for Pediatric Melanoma**

A = <b>A</b> symmetry/ <b>A</b> melanocytic (flesh colored, pink, red, pyogenic granuloma-like appearance)
B = irregular <b>B</b> orders/ <b>B</b> leeding (ulceration), bumps (papulonodules, raised lesions)
C = uneven <b>C</b> olor distribution or uniformity
D = <b>D</b> e novo development, any <b>D</b> iameter (may be <6 mm)
E = <b>E</b> volution (increase in diameter or elevation)

*Adapted from Cordoro KM, Gupta D, Frieden IJ, McCalmont T, Kashani-Sabet M. Pediatric melanoma: results of a large cohort study and proposal for modified ABCD detection criteria for children. J Am Acad Dermatol. 2013;68(6):913–925.*

genomic sequencing may help to definitively differentiate these melanocytic lesions in the near future. We recommend that patients with a diagnosis of Spitz tumors/nevi be referred to specialized cancer centers for diagnostic confirmation and additional evaluation.

### Tumor Staging and Treatment

The diagnostic and tumor staging evaluation of melanoma includes full excision of the lesion, assessment of regional lymph nodes, and evaluation of distant metastatic disease. Melanoma thickness determines the extent of the surgical resection and subsequent lymph node evaluation. The use of sentinel lymph node (SLN) biopsy, a surgical procedure that allows the identification of micrometastasis in the regional lymph node basin, is controversial in pediatric patients with melanoma and should be addressed on a case-by-case basis. Some authors recommended that SLN biopsy be performed in patients with lesions measuring more than 1 mm in thickness or thin lesions (<1 mm) with unfavorable features, such as ulceration or a high mitotic rate. Patients with clinical evidence of locoregional tumor involvement (enlarged lymph nodes) would need a complete blood cell count, serum lactate dehydrogenase levels, and CT scans of the chest, abdomen, and pelvis. Patients with evidence of distant metastases on CT images may also require an MRI of the brain and whole-body PET/CT to complete tumor staging and guide further treatment.

In the absence of pediatric-specific disease staging and treatment recommendations, treating physicians generally follow adult guidelines. The most important predictor of prognosis for pediatric melanoma is stage at diagnosis. Overall survival for pediatric patients with melanoma, considering all disease stages, is 90%. Surgical excision is the



treatment of choice for localized melanoma. The recommended margins vary based on thickness of the lesion, from 0.5 cm for melanoma in situ to 2 cm for tumor thickness greater than 2 mm. However, cosmetic and functional aspects should be taken into consideration in children because these margins may not be feasible or necessary. The recommendation that regional lymphadenectomy should be considered in patients with positive SLN is based on data from adult melanoma clinical trials. However, this procedure carries significant risks, including surgical site infection, lymphedema, and nerve injury. Moreover, there is no clear evidence that performing regional lymphadenectomy in children with positive SLNs decreases local tumor recurrence or increases survival. Pediatric patients with positive SLNs who do not undergo regional lymphadenectomy should be monitored closely with frequent clinical evaluations and ultrasonography surveillance of the positive nodal basin. Regional lymphadenectomy is recommended in pediatric patients who present with clinical evidence of regional lymph node involvement that is confirmed by histologic analysis.

Pediatric patients with high-risk melanoma can receive adjuvant therapy with high-dose interferon alfa-2b, although recently, immunotherapy and targeted therapy are more favored treatment approaches. The use of immunotherapy to treat metastatic melanoma constitutes a milestone in the history of cancer research and treatment. Ipilimumab, a monoclonal antibody that binds CTLA-4 and boosts the immune system response against cancer cells, is approved to treat adults and children older than 12 years with unresectable or metastatic melanoma. Currently, there are several clinical trials aiming to study the effect of different anticancer agents, such as pembrolizumab (PD-1 inhibitor), dabrafenib (BRAF inhibitor), and ipilimumab (CTL-4 antibody) in younger children with melanoma. The results of

these ongoing clinical trials may significantly affect the clinical outcome of pediatric patients with metastatic or recurrent melanoma.

## ACKNOWLEDGMENT

The authors thank Dr Rajkumar Venkatramani of Texas Children's Cancer and Hematology Centers, Department of Pediatrics, Baylor College of Medicine, for his helpful comments.

## Summary

- Based on strong research evidence, the incidence and type of malignant solid tumors are different in adolescents and young children.
- Based on strong research evidence, melanoma and thyroid cancers are common malignancies in adolescents; therefore, comprehensive skin and thyroid gland examinations should be performed as part of regular well-child care visits in this population.
- Based on strong research evidence, malignant solid tumors in adolescents are managed by surgery, chemotherapy, and radiotherapy depending of the tumor type and stage. Children with cancer should be promptly referred to specialized centers for appropriate diagnosis and treatment.
- Based on strong research evidence, the enrollment of adolescents with cancer in clinical trials should be considered to optimize different treatment approaches and reduce the development of long-term health problems.

*Suggested Readings for this article are at <http://pedsinreview.aappublications.org/content/39/9/444>.*

## PIR Quiz

There are two ways to access the journal CME quizzes:

1. Individual CME quizzes are available via a handy blue CME link under the article title in the Table of Contents of any issue.
2. To access all CME articles, click "Journal CME" from Gateway's orange main menu or go directly to: <http://www.aappublications.org/content/journal-cme>.
3. To learn how to claim MOC points, go to: <http://www.aappublications.org/content/moc-credit>.

1. A 3-year-old boy, new to your practice, is brought by his parents for an initial visit. On physical examination he is noted to have a left undescended testicle. The right testicle is palpated in the scrotal sac and is of normal size. You discuss with the parents the plan of care. Which of the following is the best next step in the management of this patient?
  - A. Annual screening of  $\alpha$ -fetoprotein levels.
  - B. Annual testicular ultrasonography.
  - C. Gonadectomy.
  - D. Hormone therapy if the testicle does not descend by the time he reaches full adult height.
  - E. Orchiopexy before puberty.
2. A 14-year-old boy with a history of retinoblastoma as an infant presents with pain in his left thigh. A radiograph of the left leg reveals a periosteal reaction with a sunburst pattern in the metaphysis of the distal femur. Which of the following is the most likely diagnosis in this patient?
  - A. Ewing sarcoma.
  - B. Chondrosarcoma.
  - C. Metastatic retinoblastoma.
  - D. Osteomyelitis.
  - E. Osteosarcoma.
3. A 16-year-old girl presents with a 1-month history of fever, fatigue, weight loss, and pain on the chest wall. On physical examination there is a palpable 5-cm soft tissue mass overlying the fifth rib. Which of the following is the most likely diagnosis in this patient?
  - A. Ewing sarcoma.
  - B. Germ cell tumor.
  - C. Melanoma.
  - D. Osteomyelitis.
  - E. Osteosarcoma.
4. A 15-year-old girl, who received treatment for medulloblastoma at 4 years of age, presents for a routine health maintenance visit. On physical examination there is a nontender mass over her thyroid gland and associated cervical lymphadenopathy. Diagnostic evaluation confirms the diagnosis of papillary thyroid cancer. Which of the following is the most appropriate initial management in this patient?
  - A. Lateral neck dissection.
  - B. Neoadjuvant chemotherapy.
  - C. Radiation to the neck.
  - D. Radioactive iodine ablation.
  - E. Total thyroidectomy.
5. A 16-year-old boy with a history of cardiac transplant at 8 years of age presents for a routine health maintenance visit. On physical examination a skin lesion is noted on the back of his neck. Which of the following features of this skin lesion would be most concerning for melanoma in this patient?
  - A. Flat (nonraised) appearance.
  - B. Hyperpigmentation.
  - C. Regular borders.
  - D. Symmetry.
  - E. Ulceration.

**REQUIREMENTS:** Learners can take *Pediatrics in Review* quizzes and claim credit online only at: <http://pedsinreview.org>.

To successfully complete 2018 *Pediatrics in Review* articles for AMA PRA Category 1 Credit<sup>TM</sup>, learners must demonstrate a minimum performance level of 60% or higher on this assessment. If you score less than 60% on the assessment, you will be given additional opportunities to answer questions until an overall 60% or greater score is achieved.

This journal-based CME activity is available through Dec. 31, 2020, however, credit will be recorded in the year in which the learner completes the quiz.



2018 *Pediatrics in Review* now is approved for a total of 30 Maintenance of Certification (MOC) Part 2 credits by the American Board of Pediatrics through the AAP MOC Portfolio Program. Complete the first 10 issues or a total of 30 quizzes of journal CME credits, achieve a 60% passing score on each, and start claiming MOC credits as early as October 2018. To learn how to claim MOC points, go to: <http://www.aappublications.org/content/moc-credit>.

## Pediatric Solid Tumors in Children and Adolescents: An Overview

Wendy Allen-Rhoades, Sarah B. Whittle and Nino Rainusso

*Pediatrics in Review* 2018;39;444

DOI: 10.1542/pir.2017-0268

<b>Updated Information &amp; Services</b>	including high resolution figures, can be found at: <a href="http://pedsinreview.aappublications.org/content/39/9/444">http://pedsinreview.aappublications.org/content/39/9/444</a>
<b>References</b>	This article cites 5 articles, 1 of which you can access for free at: <a href="http://pedsinreview.aappublications.org/content/39/9/444.full#ref-list-1">http://pedsinreview.aappublications.org/content/39/9/444.full#ref-list-1</a>
<b>Subspecialty Collections</b>	This article, along with others on similar topics, appears in the following collection(s): <b>Medical Education</b> <a href="http://classic.pedsinreview.aappublications.org/cgi/collection/medical_education_sub">http://classic.pedsinreview.aappublications.org/cgi/collection/medical_education_sub</a> <b>Journal CME</b> <a href="http://classic.pedsinreview.aappublications.org/cgi/collection/journal_cme">http://classic.pedsinreview.aappublications.org/cgi/collection/journal_cme</a> <b>Hematology/Oncology</b> <a href="http://classic.pedsinreview.aappublications.org/cgi/collection/hematology:oncology_sub">http://classic.pedsinreview.aappublications.org/cgi/collection/hematology:oncology_sub</a> <b>Cancer/Neoplastic</b> <a href="http://classic.pedsinreview.aappublications.org/cgi/collection/cancer:neoplastic_sub">http://classic.pedsinreview.aappublications.org/cgi/collection/cancer:neoplastic_sub</a> <b>Adolescent Health/Medicine</b> <a href="http://classic.pedsinreview.aappublications.org/cgi/collection/adolescent_health:medicine_sub">http://classic.pedsinreview.aappublications.org/cgi/collection/adolescent_health:medicine_sub</a>
<b>Permissions &amp; Licensing</b>	Information about reproducing this article in parts (figures, tables) or in its entirety can be found online at: <a href="https://shop.aap.org/licensing-permissions/">https://shop.aap.org/licensing-permissions/</a>
<b>Reprints</b>	Information about ordering reprints can be found online: <a href="http://classic.pedsinreview.aappublications.org/content/reprints">http://classic.pedsinreview.aappublications.org/content/reprints</a>



## **Pediatric Solid Tumors in Children and Adolescents: An Overview**

Wendy Allen-Rhoades, Sarah B. Whittle and Nino Rainusso

*Pediatrics in Review* 2018;39:444

DOI: 10.1542/pir.2017-0268

The online version of this article, along with updated information and services, is located on the World Wide Web at:

<http://pedsinreview.aappublications.org/content/39/9/444>

Pediatrics in Review is the official journal of the American Academy of Pediatrics. A monthly publication, it has been published continuously since 1979. Pediatrics in Review is owned, published, and trademarked by the American Academy of Pediatrics, 345 Park Avenue, Itasca, Illinois, 60143. Copyright © 2018 by the American Academy of Pediatrics. All rights reserved. Print ISSN: 0191-9601.

# American Academy of Pediatrics

DEDICATED TO THE HEALTH OF ALL CHILDREN®

